

# Resolution™ Clip

TECHNIQUE SPOTLIGHTS

*Esophagus*

*Stomach/  
Duodenum*

*Colon*



**Boston  
Scientific**

# ESOPHAGUS

- › Hemoclipping of a Mallory-Weiss Tear
- › Treatment of Mucosal Tears in the Esophagus
- › Closure of an Esophageal Perforation
- › Closure of an Esophageal Laceration

Case Presented by:  
**MATHEW SERICATI, M.D.**

*Idaho Gastroenterology Associates  
and St. Luke's Regional Medical Center  
Boise, Idaho, USA*

CASE 1

## Hemoclipping of a Mallory-Weiss Tear

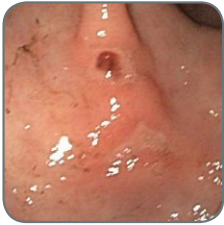

Figure 1

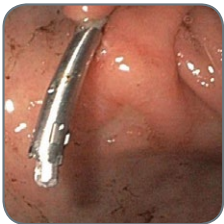

Figure 2

### HISTORY

A 67-year-old man presented to the emergency room via ambulance with melanic stools and hematemesis. He was on a flight from Seattle to Denver when his flight was diverted to Boise after multiple bouts of hematemesis and a syncopal episode. Three days prior to the flight he reported melanic stools but was otherwise doing well. He became light-headed and was brought to his gate by wheelchair, but progressed to multiple episodes of hematemesis and a syncopal episode in the air. Past medical history was significant for osteoarthritis and gout for which he was taking indocin and allopurinol. Upon presentation to the emergency room, his blood pressure was 80/40 with a pulse in the 120s. His hemoglobin was 9.9, platelets 243, and INR was 1.0. After his blood pressure was stabilized with IVFs and blood transfusions, the patient underwent urgent EGD.

### PROCEDURE

Multiple superficial ulcers were noted throughout the stomach. A 1cm ulcer with a visible vessel was present in the antrum of the stomach. The visible vessel (Figure 1) measured approximately 1.5mm and had evidence of recent bleeding. An injection of 3cc of 1:10,000 epinephrine into the visible vessel was performed. A Resolution Clip was placed on the visible vessel with excellent hemostasis (Figure 2). A 1cm Mallory-Weiss Tear was also noted at the GE junction with evidence of recent bleeding (felt to be the secondary bleeding site from retching). This was treated with bipolar electrocoagulation from a 7Fr Probe™ Electrohemostasis Catheter (Figure 3). After use of the Gold Probe Catheter, a Resolution Clip was placed to approximate the margins and provide good hemostasis (Figure 4).

### POST PROCEDURE

The patient was admitted to the intensive care unit overnight and placed on a Proton-Pump Inhibitor (PPI) drip. He clinically remained stable, had no further evidence of GI bleeding and did not require additional blood transfusions. He was discharged shortly after. Since being discharged from the hospital, he has not had any further bleeding and has not yet undergone his eight week follow up EGD.

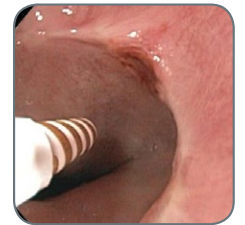

Figure 3

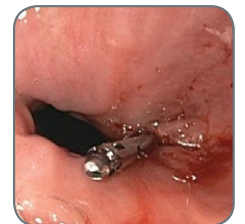

Figure 4

*Images provided courtesy of Dr. Sericati*



Case Presented by:

**ADOLFO PARRA-BLANCO, M.D.**

*Department of Gastroenterology,*

*Canarias University Hospital,*

*Santa Cruz de Tenerife, Spain*

CASE 2

## Treatment of Mucosal Tears in the Esophagus with Endoscopic Clips

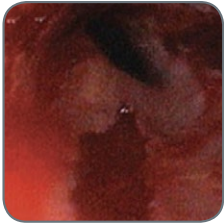


Figure 1

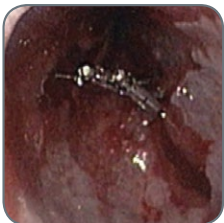

Figure 2

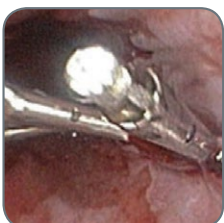


Figure 3

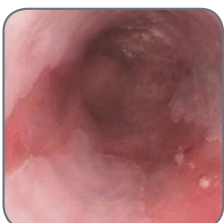


Figure 4

### HISTORY

A 73-year-old male underwent an upper endoscopy for the study of long-standing reflux symptoms. The examination was done under conscious sedation with poor tolerance, in spite of the administration of 100 µg of Fentanyl and 7 mg of Midazolam, and nausea accounted repeatedly during the procedure.

During the initial passage of the endoscope in the esophagus, a long segment of Barrett's esophagus was detected, with no other gross abnormalities. On withdrawal, two tears were found in the lower end of the columnar epithelium, proximally to the cardia: a shallow 1 cm tear (located at 6 o'clock – Figure 1) and a deep 3 cm tear (located at 3 o'clock – Figure 1).

### PROCEDURE

The affected area was flushed with water in order to have a clear view of the lesion. The bottom of the tear was inspected in detail and no signs of perforation were evident. There was some oozing from the tear and a decision was made to suture the mucosal defect in order to prevent further complications such as delayed bleeding or perforation.

Five Resolution Clips were applied and attached consecutively in a distal to proximal order (Figure 2). The reason for this is that the clips initially applied may hamper the precise application of further clips, and it is easier to check the mucosal defect remaining to be sutured if the direction is from distal to proximal. This aspect is important, because although clipping is considered to be almost devoid of any risks, there is a possibility that a clip incorrectly placed at the bottom of a mucosal defect instead of grasping normal mucosa at the edge of the lesion can result in a perforation.

The tear was successfully sutured with five Resolution Clips, which were placed easily (Figure 3). The extent of the Barrett's esophagus was C5M8 according to the Prague Classification. No biopsies were taken to confirm the diagnosis. The patient remained asymptomatic and was discharged after observation.

### POST PROCEDURE

The patient was on high dose Proton-Pump Inhibitor (PPI). Four months later in a second endoscopy, no trace of the tear was found, but random biopsies revealed high-grade dysplasia in the Barrett's epithelium. A third endoscopy was performed in order to try to locate any dysplastic areas, and two small erosions were found in a Barrett's tongue (Figure 4). Biopsy taken from both areas revealed high-grade dysplasia and an endoscopic mucosectomy is planned.

Mucosal tears in the esophagus may occur during diagnostic or therapeutic endoscopy, but they are very infrequent and underlying conditions such as eosinophilic esophagitis should be ruled out. The Resolution Clip Devices are a valuable tool for intraprocedural complications (bleeding and perforations).

*Images provided courtesy of Dr. Parra-Blanco*

Case Presented by:  
**BRIAN J. DUNKIN, M.D., FACS**

Associate Professor of Surgery, Chief,  
Division of Laparoendoscopic Surgery  
The University of Miami, Miller School of Medicine, Miami, FL

CASE 3

## Closure of an Esophageal Perforation with Endoscopic Clips

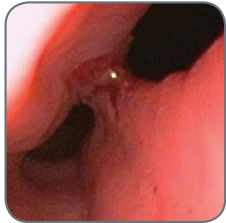

Figure 1

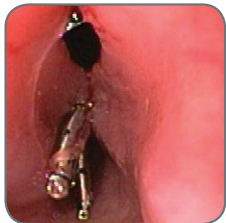

Figure 2

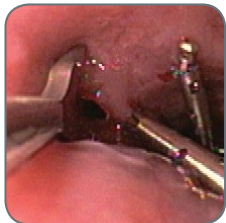

Figure 3

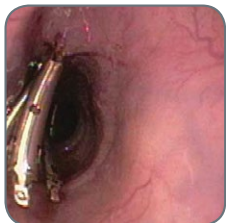


Figure 4

### HISTORY

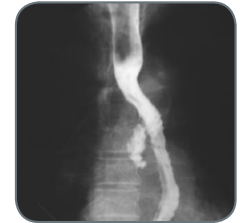A 76-year-old woman presented to the Emergency Room with signs and symptoms consistent with cholangitis. Her work-up confirmed an elevated white blood cell count and bilirubin, and an ultrasound of the abdomen revealed cholecystolithiasis with a dilated common bile duct and a possible filling defect in the distal duct. An urgent ERCP was done which demonstrated choledocholithiasis, but was unsuccessful in retrieving the stone. A biliary stent was placed for decompression and the patient was referred to our institution for definitive therapy. Of note, the patient has a remote history of severe lung infection with “pleurisy” and possible tuberculosis.

### PROCEDURE

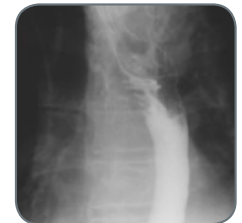An attempt was made to repeat the ERCP. During initial passage of the duodenoscope, mild resistance was felt at about the mid-esophageal level. The duodenoscope was immediately removed and a gastroscope introduced to inspect the esophagus. In the mid-esophagus, 27cm from the incisors, a 2cm hole was identified (Figure 1). It was felt that this may be a perforated traction diverticulum, possibly related to the patient’s prior history of inflammation of the lung. The distal esophagus appeared normal, as did the stomach and duodenum. The biliary stent was no longer in place. Beginning distally and working proximally, six Resolution Clips were used to close the perforation (Figures 2, 3, and 4). Upon completion, the closure appeared secure.

The patient was subsequently monitored in the intensive care unit and treated supportively with parenteral nutrition and broad spectrum antibiotics. A chest tube was also required for a right pneumothorax. Thirty-six hours after admission, she developed slight tachycardia and a low grade temperature elevation. A barium esophagram was obtained which demonstrated a contained leak from the area of the clips (X-ray 1). The patient was monitored further with resolution of her tachycardia and normalization of her temperature curve. Ten days later a repeat esophagram was done which showed no leak (X-ray 2). The patient was subsequently advanced to a full liquid diet and discharged to home.

Two months later, the patient continued to feel well and was tolerating a regular diet. It is planned for her to undergo a laparoscopic cholecystectomy and intraoperative cholangiogram. If she has choledocholithiasis, a surgical common bile duct exploration will be performed.



X-ray 1



X-ray 2

Images provided courtesy of Dr. Dunkin



Case Presented by:

**JONATHAN M. BUSCAGLIA, M.D.**

*Director of Interventional Endoscopy*

*Assistant Professor of Medicine*

*Stony Brook University Medical Center*

*State University of New York at Stony Brook, USA*

## CASE 4

# Spiral Overtube-Related Esophageal Laceration Successfully Treated with the Application of Multiple Resolution Clips

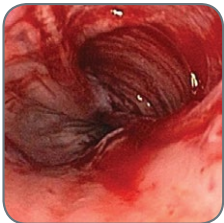

Figure 1

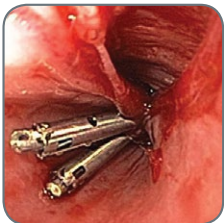


Figure 2

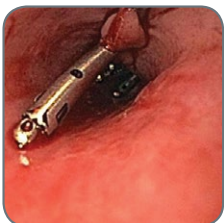

Figure 3

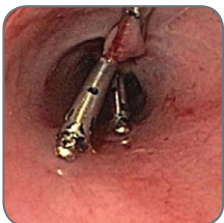

Figure 4

## HISTORY

A 78-year-old female presented with melena and refractory iron-deficiency anemia requiring several blood transfusions. She had a history of valvular heart disease and hypertension. Upper endoscopy and colonoscopy were both negative. A wireless capsule endoscopy study was performed and revealed multiple bleeding angioectasias within the proximal and mid small intestine. Referral to our center was made for subsequent deep enteroscopy procedure.

## PROCEDURE

An antegrade (per os) spiral overtube-assisted deep enteroscopy was performed under general anesthesia. The enteroscope was advanced into the proximal ileum. Several non-bleeding angioectasias were noted in the proximal and mid jejunum. Argon plasma coagulation was used to ablate all visible lesions, and the enteroscope and overtube were then both withdrawn. Upon inspection of the distal esophagus, a slightly less than 3cm mucosal laceration was noted which penetrated down to the circular muscle layer of the esophageal wall (Figure 1). Beginning at the most distal end of the laceration, a total of five Resolution Clips were readily deployed in longitudinal fashion in order to completely close the defect all the way to its most proximal edge (Figures 2-4).

## OUTCOME

The patient recovered from anesthesia without any discomfort or signs of perforation. She was discharged from the endoscopy unit on liquid diet for 24 hours and soft food for one week. During follow up at one week and three months after the procedure, the patient denied any complaints of dysphagia, painful swallowing, chest discomfort, or additional symptoms of concern. Her hemoglobin level remained stable for the first time in over two years.

## DISCUSSION

This case highlights the utility of the Resolution Clip for the treatment of gastrointestinal pathology which does not directly involve bleeding lesions such as ulcers or aberrant vessels. The flexibility of the Resolution Clip deployment catheter allowed for quick application of multiple clips even through the working channel of a long, 200cm enteroscope device. In addition, the Resolution Clip's wide jaw diameter enabled excellent apposition of the tissue margins despite the significant width of the mucosal defect.

*Images provided courtesy of Dr. Buscaglia*

# STOMACH/DUODENUM

- › Closure of a Large Gastric Defect
- › Closure of a Gastrocutaneous Fistula
- › Gastric Hemostasis
- › Hemostasis of Post-EMR Bleeding
- › Management of a Large Gastric Polyp
- › Closure of a Gastric EMR Site
- › Hemostasis of Actively Bleeding Gastric Polyps
- › Closure of a Duodenal Perforation after ESD

Case Presented by:

**PING-HONG ZHOU, M.D., PH.D**

**MING-YAN CAI, M.D.; LI-QING YAO, M.D.**

*Endoscopy Center, Zhongshan Hospital*

*Fudan University, Shanghai, CHINA*

CASE 5

## Closure of a Large Gastric Defect with Resolution Clips After Endoscopic Submucosal Dissection in the Gastric Fundus

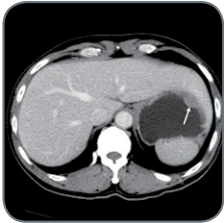


Figure 1

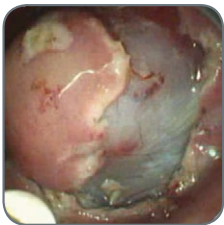

Figure 2

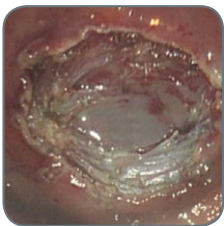

Figure 3

### HISTORY

A 59-year-old male came for an endoscopy examination with a complaint of six-month history of abdominal fullness. The exam revealed a submucosal tumor in the gastric fundus. Endoscopic ultrasonography showed it originated from the muscularis propria (MP) layer, measuring 2.2×1.2cm in diameter. An abdominal CT scan with contrast was arranged. The lesion was mainly intraluminal growing (Figure 1). He was admitted to our endoscopy unit for endoscopic resection of the tumor.

### PROCEDURE

A standard endoscopic submucosal dissection (ESD) was performed for this patient. After mucosal marking, submucosal injection, precutting of the mucosal and submucosal layers around the lesion were performed with a hook knife. A circumferential incision was made as deep as the MP layer using an insulated-tip knife (Figure 2). The submucosal tumor was carefully dissected en bloc from the serosa, leaving the serosal layer intact (Figure 3). The resulting large gastric defect (< 3cm) was successfully closed using Resolution Clips.

We first narrowed the wound by air suction. Then we used the tip of the clip jaw to hook one side of the mucosa and grasped the other side within the span. The deployment of the first Resolution Clip made the wound a linear one (Figure 4). The following clips were deployed uneventfully and the huge wound was sealed perfectly (Figure 5). The entire procedure took 25 minutes (from mucosal marking to specimen retrieval).

### POST PROCEDURE

The patient was on nothing by mouth after surgery. Post procedure medication included a proton pump inhibitor, antibiotics and haemostatics. The patient was observed for signs of abdominal pain, abdominal distension and peritonitis. None were observed. The patient was on a postoperative fluid diet on day two and discharged uneventfully on day three.

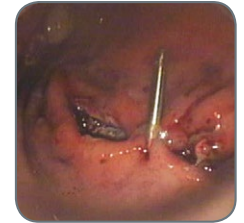

Figure 4

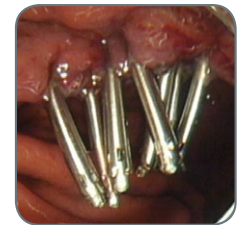

Figure 5



Continued on Next Page

*Images provided courtesy of Dr. Zhou, Dr. Cai and Dr. Yao*





## Closure of a Large Gastric Defect with Resolution Clips After Endoscopic Submucosal Dissection in the Gastric Fundus

Case Presented by:

**PING-HONG ZHOU, M.D., PH.D**

**MING-YAN CAI, M.D.; LI-QING YAO, M.D.**

*Endoscopy Center, Zhongshan Hospital*

*Fudan University, Shanghai, CHINA*

### DISCUSSION

The successful closure of gastric defect after ESD procedure for MP-derived lesions is crucial to prevent gastrointestinal (GI) leakage and leads to the earlier healing of the wound. In this case, the tumor was located in a very difficult place for ESD procedure, the gastric fundus. The re-open and re-close functions of the Resolution Clip enables the easier repositioning of the clips. The deployment of the first clip was very important in this case, because it made the wound a linear one which is much easier for the deployment of the following clips. Effective closure of the wound is required for submucosal lesions originating from deep layers of the gastric wall. The cost effectiveness of clips makes this a mainstream option for closure procedures. The jaw span of Resolution Clip is 11mm-wide, ensuring a strong and deep grasp of the tissue, thus preventing delayed perforation and GI leakage. This case illustrates the effectiveness of Resolution Clips for closing a large gastric defect after ESD procedure for an MP-derived submucosal tumor in the gastric fundus, allowing safe and rapid recovery for this patient.

 [Previous Page](#)



Case Presented by:

**KIMBERLY J. KOLKHORST, D.O.**  
**PATRICK BRADY, M.D.**

*Division of Digestive Diseases  
University of South Florida  
Tampa, FL, USA*

CASE 6

## Endoscopic Clip Closure of a Gastrocutaneous Fistula in a Patient with History of Tucker Dilation via Gastrostomy

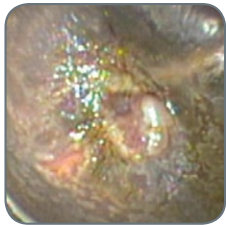

Figure 1

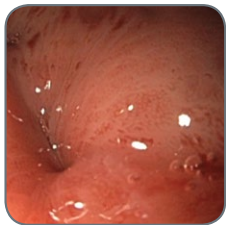


Figure 2

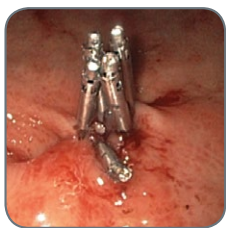

Figure 3

### HISTORY

A 56-year-old female with a history of laryngeal cancer (status post-neck radiation and total laryngectomy approximately 20 years prior), presented with complaints of dysphagia and was found to have a severe proximal esophagus radiation-induced stricture. A percutaneous radiological gastrostomy (PRG) was subsequently placed to improve nutrition.

Over the course of 17 months, the patient underwent 18 esophagogastroduodenoscopies (EGD) with Tucker dilation via the gastrostomy up to 38 Fr. Successful Savary dilation was eventually achieved and Tucker dilation was no longer required. The PRG was removed 10 months after placement. Fourteen days after PRG removal the patient was noted to have persistent leakage from a gastrocutaneous fistula (GCF) at prior gastrostomy (Figure 1). The EGD revealed a hole in the anterior wall of the stomach, approximating 8mm (Figure 2). Attempted closure of the fistula using internal and external interrupted silk sutures was unsuccessful.

### PROCEDURE

An EGD with endoscopic clip placement using one Resolution Clip to approximate the margins of the fistulous tract was performed. A decreased fistula output was noted after clip placement but leakage persisted. An EGD was repeated one week later with placement of five endoscopic clips (Figure 3) resulting in immediate closure of the gastrocutaneous fistula.

### POST PROCEDURE

Endoscopic evaluation four months after endoscopic clip placement revealed four clips in place and persistent closure of the GCF (Figure 4). A repeat EGD 16 months after endoscopic clip placement revealed one clip in place with a well-healed gastric mucosa (Figure 5).

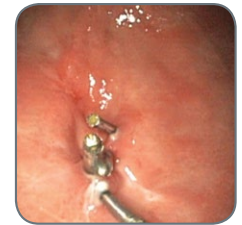

Figure 4

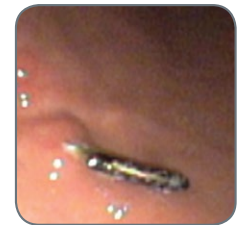

Figure 5

▶ Continued on Next Page

*Images provided courtesy of Dr. Kolkhorst and Dr. Brady*

CASE 6 CONTINUED

## Endoscopic Clip Closure of a Gastrocutaneous Fistula in a Patient with History of Tucker Dilation via Gastrostomy

Case Presented by:

**KIMBERLY J. KOLKHORST, D.O.**  
**PATRICK BRADY, M.D.**

*Division of Digestive Diseases  
University of South Florida  
Tampa, FL, USA*

### DISCUSSION

---

Refractory gastrocutaneous fistulas are a known consequence following gastrostomy removal that can be very difficult to manage. Conservative management of GCFs has had limited success. Surgical laparotomy and excision of the fistulous tract is often required but results in increased morbidity and mortality, especially in debilitated patients.

Endoscopic clipping of GCFs involves grasping the mucosal and submucosal tissue layers at the fistulous tract edges and approximating the opposite walls, thus leading to macroscopic closure of the fistula opening. This case illustrates that endoscopic clip placement is a valuable modality for closing refractory gastrocutaneous fistulas and is a promising alternative to surgery.

 [Previous Page](#)

[Home](#)

[Esophagus](#)

[Stomach/Duodenum](#)

[Colon](#)

 [Prev Case](#)

[Next Case](#) 

Case Presented by:

**SERGEY V. KANTSEVOY, M.D., PH.D**

*The Melissa L. Pozner Institute for Digestive Health and Liver Disease at Mercy Medical Center  
Baltimore, Maryland, USA*

CASE 7

## Resolution Clip Facilitates Endoscopic Hemostasis, Improving Visibility and Access to Bleeding Vessel

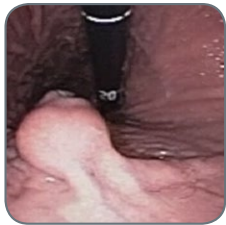

Figure 1

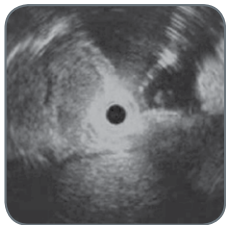

Figure 2

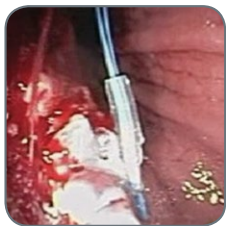

Figure 3

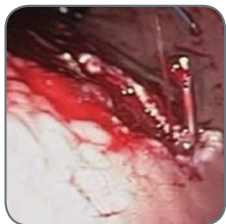


Figure 4

### HISTORY

A 74-year-old woman with multiple medical problems (hypertension, diabetes mellitus, coronary artery disease, chronic renal insufficiency on hemodialysis) became weak, dizzy and lost consciousness at home. She was brought to the emergency room by ambulance and was found to have anemia (Hematocrit = 22). An emergency upper endoscopy revealed an ulcerated mass 2 by 3cm inside the stomach (Figure 1). Because the risk of recurrent bleeding from the ulcerated gastric lesion was high, she was referred to us for endoscopic resection of the lesion.

### PROCEDURE

An endoscopic ultrasound was performed and demonstrated hypoechoic rounded gastric lesions located in the submucosal layer of the gastric wall with a clearly seen large vessel inside the lesion (Figure 2). To prevent the bleeding from this vessel, a PolyLoop™ Snare was applied to the base of the lesion. However, after the lesion was resected with a snare, the PolyLoop Snare fell off and a severe arterial bleed started (Figure 3).

Unfortunately, the bleeding vessel was located under the mucosal margin of the incision and it was impossible to visualize and to access this vessel for hemostasis. In this situation, we applied one Resolution Clip to the site of the vessel's origination. Application of the clip slowed down the bleeding but, more importantly, it pulled the mucosal margin away and clearly demonstrated the origin of the bleeding vessel (Figure 4). Then the definitive hemostasis was easily achieved (Figure 5).

### POST PROCEDURE

The pathological examination of the removed lesion (Figure 6) revealed a gastric carcinoid. The patient tolerated the procedure well and was discharged home two days after endoscopy in stable condition. An upper endoscopy was repeated in three months and demonstrated a well healed scar at the site of the endoscopic mucosal resection without any remaining carcinoid tissue (Figure 7). The patient did not have any other episodes of gastrointestinal bleeding.

### CONCLUSIONS

This case demonstrates additional value of the Resolution Clip in difficult cases of endoscopic hemostasis. If the bleeding vessel cannot be directly approached initially, application of the Resolution Clip can slow the rate of bleeding and may alter the local anatomy, providing favorable conditions for definitive endoscopic hemostasis.

*Images provided courtesy of Dr. Kantsevov*

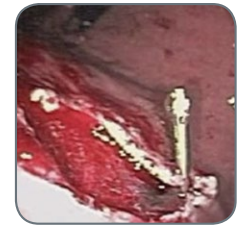


Figure 5

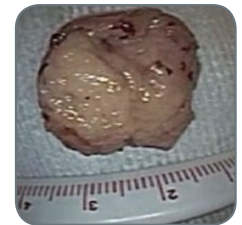


Figure 6

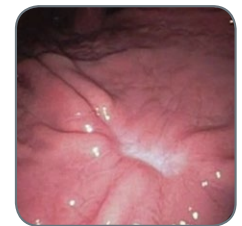

Figure 7

## Treatment of Post-EMR Bleeding with Endoscopic Clips

Case Presented by:

**NESTOR CHOPITA, M.D., FRANCISCO TUFARE, M.D.,  
NELSON CONDADO, M.D., BÁRBARA AMENDOLARA, M.D.**

*Gastroenterology Department,  
Hospital San Martín de La Plata,  
Buenos Aires, Argentina*

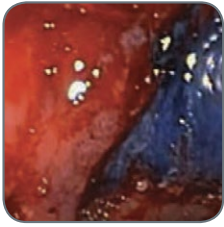


Figure 1

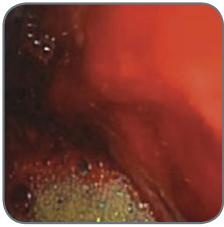


Figure 2

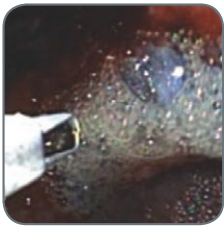


Figure 3

### HISTORY

A 62-year-old male with cirrhosis (Child B) and a history of variceal bleeding was admitted to our hospital for gastric polyposis resection.

### PROCEDURE

The endoscopy showed gastric polyposis and there was an abnormal area of mucosa on the gastric incisura. Biopsy taken from the site revealed intra-mucosal carcinoma and an endoscopic mucosal resection was performed (Figure. 1). The patient had hemodynamic instability, hematemesis and hematocrit dropped at 22% 12 hours after the procedure. Another endoscopy showed active bleeding in the EMR site (Figure 2). The bleeding was successfully managed with the use of 2 Resolution Clips (Figures 3 & 4).

### PROCEDURE

During the follow up, the patient was in good condition and there were no complications (Figure 5). Histological results confirmed early gastric cancer (EGC).

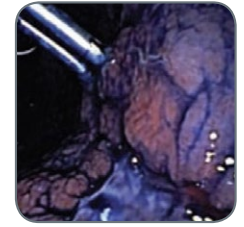


Figure 4

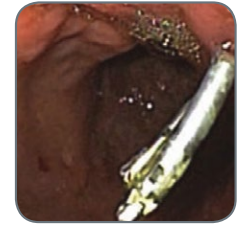

Figure 5

*Images provided courtesy of Dr. Chopita, Dr. Tufare, Dr. Condado and Dr. Amendolara*

Case Presented by:  
**DAVID A. FLOREZ, M.D.**

Medical Director,  
Elms Endoscopy Center/Trident Gastroenterology,  
Charlestown, South Carolina

CASE 9

## Management of a Large Gastric Polyp

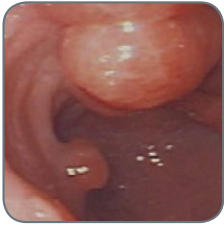

Figure 1

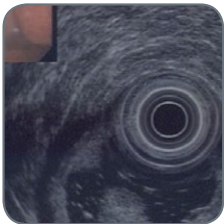

Figure 2

### HISTORY

An 81-year-old woman was referred for evaluation of weight loss and persistent nausea. Prior attempts at managing her symptoms with proton pump inhibitor therapy and promotility agents by her primary physician had failed. An EGD demonstrated a large gastric polyp at the pylorus (Figure 1), causing a functional gastric outlet obstruction. Radial Jaw™ 3 Standard Capacity Biopsy Forceps showed the polyp to be a benign hyperplastic inflammatory polyp. She was subsequently referred to me for endoscopic ultrasound evaluation (EUS) of the polyp and possible gastric polypectomy for definitive therapy.

### PROCEDURE

The patient underwent EUS examination. The gastric polyp was scanned with a radial echoendoscope, revealing a large mucosal based lesion (Figure 2). There were no significant blood vessels within the polyp. Additionally, there were no malignant features and no evidence of invasion to deeper layers of the gastric wall. No significant celiac or peri-gastric lymphadenopathy was appreciated. A standard EGD scope was then passed and the polyp was removed in a piece-meal fashion with a Sensation™ Polypectomy Snare. The polyp fragments were then withdrawn through the mouth with a basket retrieval device.

The polypectomy ulcer was then re-inspected. There was mild, persistent oozing of blood at the site (Figure 3). Given the patient's advanced age and the fact that she lived in a rural area with considerable drive time to the nearest medical facility, I elected to attempt primary closure of the site with Resolution Clips (Figure 4). The defect edges were reapproximated with three Resolution Clips achieving adequate hemostasis. The patient tolerated the procedure well and there were no peri-operative complications. Twice daily proton pump inhibitor therapy was prescribed.

### POST PROCEDURE

Final pathologic diagnosis of the polyp revealed a benign inflammatory polyp without dysplasia. On follow up, the patient's nausea had resolved and her weight had normalized.

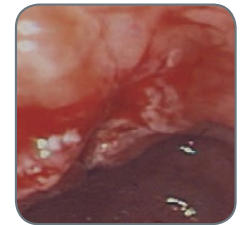


Figure 3

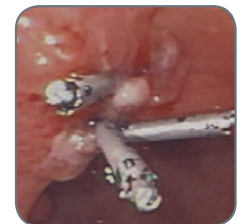

Figure 4

Images provided courtesy of Dr. Florez



Case Presented by:  
**KEVIN MCGRATH, M.D.**

*Assistant Professor of Medicine  
Director, Endoscopic Ultrasound, Medical Director, GI Lab  
University of Pittsburgh Medical Center, Pittsburgh, PA*

CASE 10

## Closure of a Gastric EMR Site

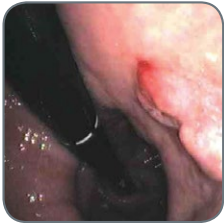

Figure 1

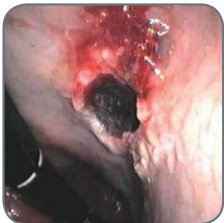

Figure 2

### HISTORY

An 87 year old woman presented with fatigue and microcytic anemia. Colonoscopy within the previous 6 months had been normal, therefore endoscopy was performed. A 1.5cm mass was found in the gastric body; biopsies revealed high grade dysplasia with focal intramucosal carcinoma. The patient was referred for EMR.

### PROCEDURE

Endoscopy revealed a large hiatal hernia and a 1.5cm sessile mass on the lesser curvature of the gastric body (Figure 1). The lesion was mucosal-based without evidence of invasion as assessed by high frequency EUS. A saline-assisted mucosal resection was successfully performed with a polypectomy snare, leaving a large defect (Figure 2). Minimal oozing was controlled with a 3 cc epinephrine (1:10,000) injection. The mucosal defect was successfully closed with four Resolution Clips (Figure 3).

### POST PROCEDURE

Pathology revealed extensive high grade dysplasia with focal intramucosal carcinoma; all margins were free of dysplastic change.

Follow up endoscopy 3 months later revealed a focal scar without evidence of residual or recurrent mass (Figure 4).

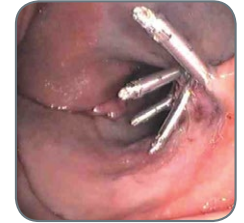

Figure 3

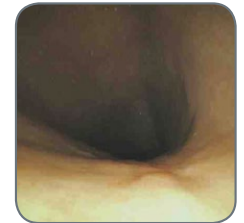


Figure 4

*Images provided courtesy of Dr. McGrath*

Case Presented by:

**JEREMY BARBER, DO**  
**WILLIAM WEATHERHEAD, M.D.**

*McLaren Greater  
Lansing Hospital  
Lansing, Michigan, USA*

CASE 11

## Hemostasis of Actively Bleeding Gastric Polyps Utilizing the Resolution Clip

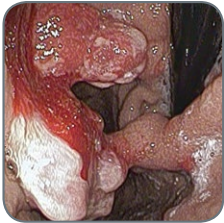

Figure 1

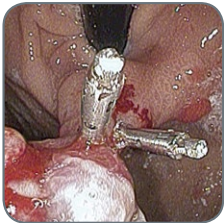

Figure 2

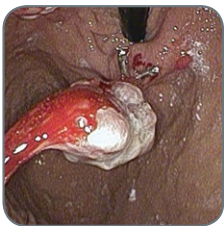

Figure 3

### HISTORY

A 61-year-old with a history of Myocardial Infarction (MI) four months prior was treated with a drug-eluting stent as well as anti-platelet agents, aspirin and prasugrel. Two months later routine CBC demonstrated Hb 9.4 with MCV 70. An esophagogastroduodenoscopy (EGD) and colonoscopy were scheduled.

The colonoscopy was unremarkable. The EGD demonstrated two large proximal gastric polyps (approx. 3cm each with large peduncles); the surface of the polyps were ulcerated.

A repeat EGD was scheduled one week later after prasugrel was held. A six pack of platelets was given one hour before the case. The follow up EGD showed two large gastric polyps in cardia with 1cm peduncles which were actively bleeding upon scope entry (Figure 1).

### PROCEDURE

A scope was maintained in the retroflexed position. A Resolution Clip was deployed on each side of the peduncle towards the center (Figure 2). There was evidence of loss of blood flow to the polyp as the polyp became dusky and shrunk in size (Figure 3). A Captivator™ II Polypectomy Snare was used to cut the polyp stalk leaving the clips in place for hemostasis on the peduncle. A third Resolution Clip was deployed in the center of the 1cm stalk for hemostasis. The polyp was then rinsed showing no further bleeding (Figure 4).

The second polyp was then treated in a similar fashion deploying two Resolution Clips across the stalk followed by a third Resolution Clip for hemostasis. This polyp was rinsed and the resected polyps were retrieved. Excellent hemostasis was noted upon scope withdraw (Figure 5). No further bleeding was noted and a repeat Hb was stable. The patient was restarted on prasugrel one day later.

It is not ideal to do polyp resections in patients that are on anti-platelet therapy; however, in this circumstance this patient was actively bleeding.

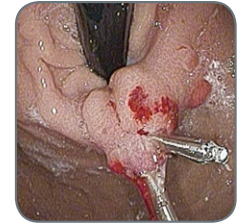

Figure 4

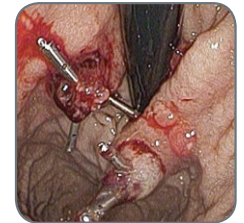

Figure 5

▶ Continued on Next Page

*Images provided courtesy of Dr. Barber and Dr. Weatherhead*

## Hemostasis of Actively Bleeding Gastric Polyps Utilizing the Resolution Clip

Case Presented by:

**JEREMY BARBER, DO**  
**WILLIAM WEATHERHEAD, M.D.**

*McLaren Greater  
Lansing Hospital  
Lansing, Michigan, USA*

### POST PROCEDURE

---

Eight weeks post procedure the patient had a repeat hemoglobin drawn; it was 14.8. During the follow up EGD, a small amount of residual tissue was noticed at each previous polypectomy site. The residual tissue was removed with a hot snare. A clip was again placed on the base of each lesion as the patient was to be restarted on the prasugrel the next day.

### DISCUSSION

---

Using two clips in opposing positions made clipping large polyp stalks feasible in the setting of this active bleed. Clipping in the retroflex position makes achieving hemostasis more complex than a typical en fosse position. Positioning hemostatic clips is always important but critical in this application. The ability to open and close the Resolution Clip, and therefore, making it repositionable, was very helpful in the success of this case. The Captivator™ II Snare is a very large, stiff-bodied 33mm snare that facilitated the proper positioning of the snare around the polyp before resection.

 [Previous Page](#)

Case Presented by:  
**ERIC C.S. LAM, M.D., FRCPC**

*Clinical Associate Professor  
Division of Gastroenterology  
University of British Columbia  
Vancouver, British Columbia, Canada*

CASE 12

## Resolution Clip Devices Used to Close Duodenal Perforation after Endoscopic Submucosal Dissection

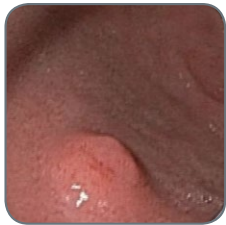

Figure 1

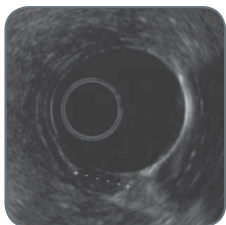


Figure 2

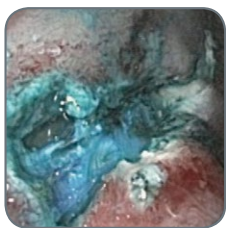


Figure 3

### HISTORY

A 56-year-old man was found to have a 10mm subepithelial lesion in the junction between the first and second part of the duodenum when undergoing an upper endoscopy to screen for Barrett's esophagus. He had a history of diabetes mellitus that was controlled with oral hypoglycemic agents. A radial endoscopic ultrasound was performed showing a 10mm hypoechoic lesion in the submucosa consistent with a duodenal carcinoid (Figures 1 and 2). Endoscopic biopsies confirmed carcinoid tumor cells. Because of the potential risk of metastatic disease and the possibility of requiring a more extensive resection, he was referred for endoscopic submucosal dissection.

### PROCEDURE

The border of the endoscopic bulge in the duodenum was marked by applying superficial cautery to the mucosal surface. A solution of 1:10,000 epinephrine and methylene blue was injected into the submucosa. Using cap assistance, a submucosal dissection was carried out around the carcinoid tumor. Upon dissecting the proximal end of the carcinoid tumor, a 5mm duodenal perforation was identified (Figure 3).

The Sensation™ Single-Use 30mm Oval Polypectomy Snare was then used to resect the carcinoid tumor immediately after the perforation was identified. Unfortunately, the intraluminal air began to enter the peritoneal space and full distension of the duodenum could not be achieved. We then applied two Resolution Clip devices to the 5mm duodenal perforation and this re-established retention of intraluminal air. An additional five Resolution Clip devices were then used to close the remaining 2.5cm mucosal defect (Figure 4).

### POST PROCEDURE

The pathology of the removed lesion showed complete excision of the carcinoid tumor. The patient was discharged two days post procedure. Repeat upper endoscopy three months after the resection showed a well epithelialized scar with no recurrence of tumor (Figure 5).

This case demonstrates the usefulness of Resolution Clip Devices in the closure of luminal perforations of the duodenum. The initial two Resolution Clip Devices with their wide jaws and closing pressure were able to take the opposing sides of the luminal perforation and to provide an adequate seal. By utilizing the Resolution Clip to close the perforation during the endoscopy, the patient was able to avoid surgery.

*Images provided courtesy of Dr. Lam*

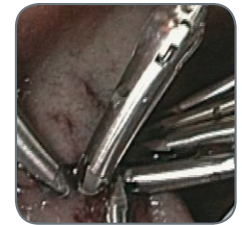

Figure 4

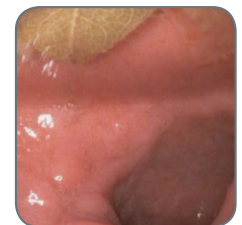


Figure 5

# COLON

- › Hemostasis of Acute Polypectomy Bleeding
- › Prevention of Post-polypectomy Hemorrhage
- › Prevention of Post-polypectomy Hemorrhage
- › Closure of Iatrogenic Perforation
- › Hemostasis of Bleeding Diverticulum
- › Hemostasis of a Colon Tumor
- › Hemostasis of Post-polypectomy Hemorrhage
- › Closure of Post-polypectomy Perforation
- › Hemostasis of a Visible Vessel
- › Closure of Post-endoscopic Resection Defect
- › Hemostasis of Post-polypectomy Bleeding
- › Closure of Post-polypectomy Defect
- › Closure of Post-EMR Perforation
- › Closure of Post-EMR Defect

CASE 13

## Endoscopic Hemostasis of Acute Bleeding During Large Polypectomy Using Resolution Clips

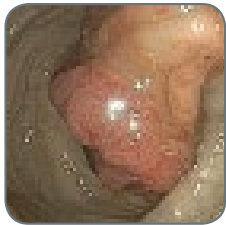

Figure 1

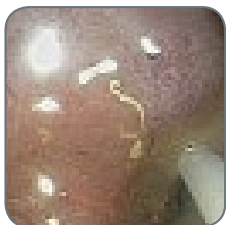

Figure 2



Figure 3

### HISTORY

A 59-year-old woman was referred for a colonoscopic polypectomy of a large (3cm) sigmoid colon polyp found during a colonoscopy by an outside referring physician. He was concerned about size of stalk and declined to snare it out because of concern of bleeding (Figure 1). He had removed a number of other smaller polyps, but left this one in for us to remove. The patient was about to undergo chemotherapy and radiation therapy for breast cancer, and needed this polyp removed as soon as possible.

### PROCEDURE

The pictures tell the rest of the story. After clearing the rest of the colon to cecum, the sigmoid polyp was resected with snare cautery, after first injecting the base with epinephrine (Figure 2). Immediate severe arterial bleeding occurred after snare excision from a large artery in the base. The resected polyp can be seen at the left of the screen (Figure 3). Spurting bleeding was stopped with a single Resolution Clip (Figures 4 and 5). The clip is positioned around the base of the bleeding artery, rotated to be parallel to the base for maximum depth of apposition. Multiple additional clips were placed for "insurance." Note that the strangulated artery that had bled can be seen protruding from between the jaws of the clip second from the bottom of the screen (Figure 6).

### POST PROCEDURE

After bleeding was controlled, the polyp was retrieved. The patient was observed in a 23-hour short stay observation overnight, had no pain or bleeding, and has done well at long term follow-up. Histopathology showed tubulovillous adenoma with no carcinoma in situ or invasive cancer, and not extending to resection margin. Within one week of the colonoscopic polypectomy, the patient commenced chemotherapy for treatment of breast cancer.

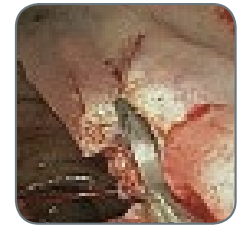

Figure 4

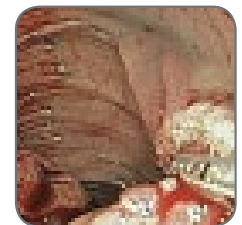


Figure 5

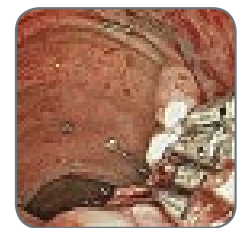


Figure 6

*Images provided courtesy of Dr. Freeman*



CASE 14

## Prevention of Post-Polypectomy Hemorrhage Using the Resolution Clip Device

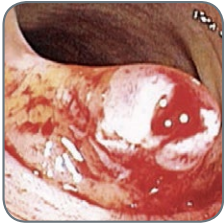

Figure 1

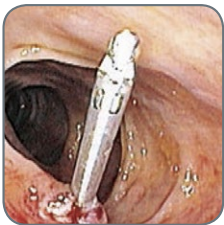


Figure 2

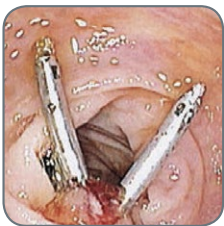

Figure 3

### HISTORY

A 91-year-old man presented with a history of anemia and hematochezia. The patient was on chronic anticoagulation therapy with Coumadin® Pharmaceutical due to porcine mitral valve replacement. Other past medical history includes a two vessel CABG, TIA, and seizure disorder. A colonoscopy was deemed necessary to explore potential sources of hematochezia. Concern was given in particular to the need for continuing anticoagulation therapy. The patient was counseled to discontinue his Coumadin Pharmaceutical therapy five days prior to the scheduled colonoscopy. Low-molecular-weight heparin was used to maintain anticoagulation until the evening prior to the procedure.

### PROCEDURE

A colonoscopy was performed, during which time a 2 cm polyp, on a thick stalk, was observed in the descending colon. This polyp was removed using a Captivator™ II Single-Use Snare and cautery techniques. Reinspection of the resection margin revealed pooling of fresh blood at the polyp stalk base (Figure 1). Two Resolution Clips were placed at the polyp stalk base with good hemostasis (Figures 2 & 3).

### POST-PROCEDURE

Low-molecular-weight heparin was resumed the morning after the procedure. There was no residual bleeding from the colon noted. Coumadin Pharmaceutical therapy was resumed 14 days post procedure and the patient has not had any further hematochezia.

*Images provided courtesy of Dr. Dean*

Case Presented by:

**ROBERT D. FANELLI, M.D., F.A.C.S.**

*Director of Surgical Endoscopy,  
Berkshire Medical Center and Surgical Specialists of  
Western New England, P.C.*

CASE 15

## Prevention of Post-Polypectomy Hemorrhage

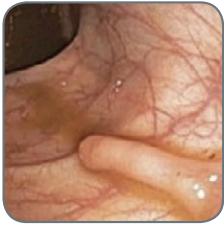

Figure 1

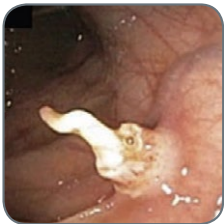

Figure 2

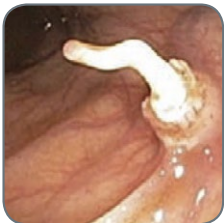

Figure 3

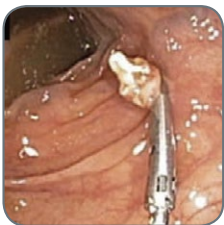

Figure 4

### HISTORY

A 73-year-old man presented for outpatient consultation because of progressive dysphagia. During the consultation, it was discovered that he had not yet undergone screening colonoscopy. With his consent, he was scheduled for sequential esophagogastroduodenoscopy (EGD) and colonoscopy in the outpatient endoscopy unit.

### PROCEDURE

The EGD revealed a distal esophageal reflux-related stricture. Biopsies were taken using Radial Jaw™ 3 Large Capacity Forceps and then the stricture was dilated using an 18-19-20 mm CRE™ Fixed Wire Balloon Dilator without incident.

Screening colonoscopy revealed, what appeared to be, seven adenomatous polyps distributed throughout the colon. One of the polyps was a long, slender, finger-like polyp in the proximal ascending colon (Figure 1). When cauterized snare polypectomy was performed, the substance of the polyp was stripped off of the underlying arterial structure that was central to its stalk (Figure 2). The vessel was not bleeding or visibly pulsing, but was turgid and standing erect. It was felt that this vessel would definitely start bleeding at some point soon (Figure 3). A single Resolution Clip was placed across the vessel at the base of the polyp, closing and reopening the clip until the perfect location was identified to occlude the vessel. The Resolution Clip was then deployed. The artery was immediately deflated and collapsed as the blood pressure within the structure was reduced to zero, virtually eliminating the risk of delayed polypectomy site hemorrhage. The shriveled up artery collapsed at the base of the polyp, just above the Resolution Clip (Figure 4).

### POST PROCEDURE

Pathologic inspection of the polyps removed during this screening colonoscopy revealed three tubular adenomas and four tubulovillous adenomas. No postpolypectomy hemorrhage occurred, and the patient's dysphagia was completely abated after esophageal dilation and the institution of proton pump inhibitor therapy.

*Images provided courtesy of Dr. Fanelli*

Case Presented by:  
**MARCO CARNIEL, M.D.**

Head of Endoscopy,  
Landeskrankenhaus Wiener Neustadt,  
Wiener Neustadt, Austria

CASE 16

## Closure of an Iatrogenic Colon Perforation with Endoscopic Clips

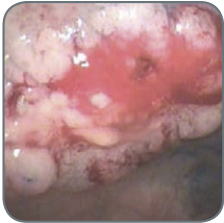

Figure 1

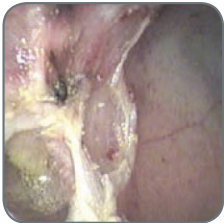

Figure 2

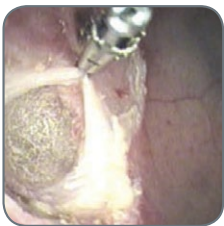

Figure 3

### HISTORY

A 72-year-old female was referred to our center for an endoscopic mucosal resection (EMR). The patient has a history of coronary heart disease, st.p. myocardial infarction in 2000, arterial hypertension, hyperlipidaemia and osteoporosis.

In February 2005, the referring hospital performed a partial rectal polypectomy. In the last pre-colonoscopy examination, a recurrent flat polypoid formation was discovered in the rectum.

### PROCEDURE

An approximately 2.5 cm flat adenoma could be seen in the rectum at 8 cm. In the center of the lesion, scar tissue after the partial polypectomy in 2005 was readily distinguishable (Figure 1)

Fluid infiltration of the polyp revealed good lifting sign. Utilizing a straight suction cap, the lesion was totally resected in 4 fragments using a piecemeal technique with a cautery snare.

A 12 mm perforation was revealed upon retrieval of the last fragment (Figure 2). By applying seven Resolution Clips, the perforation edges could be properly aligned step-by-step and the perforation successfully closed (Figures 3, 4 and 5).

### HISTOLOGICAL FINDINGS

Flat tubular partially tubulovillous adenoma with low to moderate grade intraepithelial neoplasia, the muscularis mucosae overall intact – resection in toto.

### POST-PROCEDURE

The patient was kept under clinical observation for several days. There was no increase of inflammatory parameters upon serological examination and no clinical signs of peritonitis. After 2 days, the patient was introduced to a dietary regimen which was well tolerated. A surgical intervention was not necessary and after 4 days the patient was discharged.

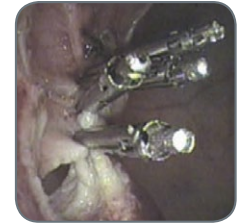

Figure 4

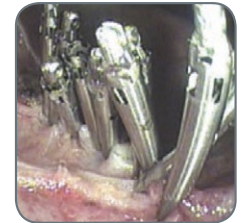


Figure 5

Images provided courtesy of Dr. Carniel

CASE 17

## Bleeding Diverticulum Closure

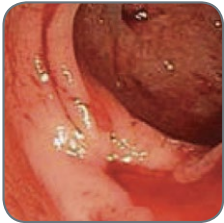

Figure 1

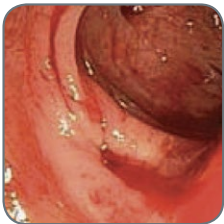

Figure 2

### HISTORY

An 83-year-old man presented with shortness of breath, generalized weakness and had been passing bright, red blood from his rectum for 48 hours.

Past medical history was significant for Chronic Obstructive Pulmonary Disease (COPD), Chronic Heart Failure (CHF) and Hypertension (HTN). Patient was treated with blood pressure medication and ASA 81 MG daily. Vital signs and physical exam appeared normal at the time of admission. Labs showed: WBC 7.3, Hgb 9.2, hematocrit 26.8, platelets 211 and an INR of 0.97. The patient had a negative bleeding scan and was prepped for a colonoscopy the following day.

### PROCEDURE

Patient prep was suboptimal. No active bleeding was seen, diverticulosis was observed up to the cecum, and bright-red blood was found in the right colon. An EGD was performed, to rule out an upper-GI source of the bleeding, which was unremarkable. Patient was transfused and a repeat colonoscopy was done the following day.

A bleeding diverticulum was noted in the sigmoid colon (Figures 1 & 2). An injection of epinephrine 1:10000 did not control the bleed. A Resolution Clip was used to approximate the diverticulum edge. A total of six Resolution Clips (Figures 3 & 4) were deployed successfully to close the edge of the diverticulum.

### POST PROCEDURE

Good hemostasis was established at the end of the procedure. The patient did not require any additional transfusion and he was discharged shortly after. A three month follow up did not show any evidence of bleeding.

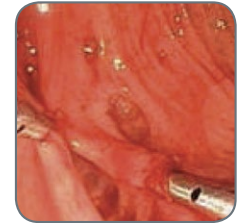

Figure 3

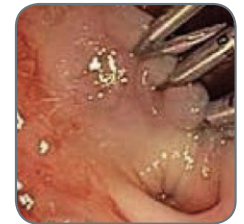

Figure 4

*Images provided courtesy of Dr. Kharrat*

Case Presented by:  
**LUIS F. LARA, M.D.**

*Assistant Professor of Internal Medicine  
Division of Digestive and Liver Diseases,  
The University of Texas, Southwestern Medical Center at Dallas*

CASE 18

## Bleeding from a Colon Tumor after Biopsy with Forceps

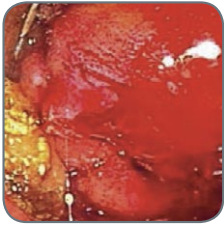

Figure 1

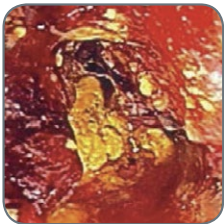


Figure 2

### HISTORY

A 42-year-old white male diagnosed with cystic fibrosis who had a bilateral lung transplant in 1997 with a single previous episode of rejection and diabetes mellitus was referred to evaluate episodic mild hematochezia and new onset constipation requiring intermittent laxative use. The patient had a previous spontaneous diverticular perforation for which he had a diverting colostomy that had been repaired three years earlier.

### PROCEDURE

The colonic anastomosis appeared normal. A circumferential, friable mass occluding the lumen to about 12 mm and measuring 4 cm in length was seen in the distal transverse colon. A standard biopsy forceps was used to biopsy the mass (Figure 1). Bleeding continued from one of the biopsy sites (estimated to be 8 mm in size), which did not stop after five minutes of irrigation and observation (Figure 2). A Resolution Clip was used to approximate the sides of the biopsy site, achieving hemostasis, which was confirmed before scope withdrawal (Figure 3). Follow-up confirmed there was no further bleeding (Figure 4).

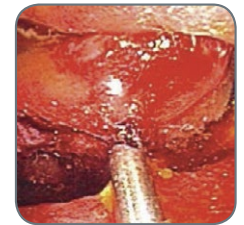


Figure 3

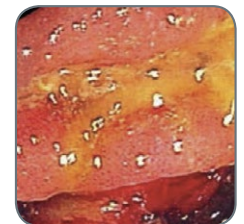

Figure 4

*Images provided courtesy of Dr. Lara*



Case Presented by:  
**SRI KOMANDURI, M.D., M.S.**

*Associate Professor of Medicine, Interventional Endoscopy  
Division of Gastroenterology and Hepatology  
Feinberg School of Medicine, Northwestern University*

CASE 19

## Post-polypectomy “Spurting” Vessel

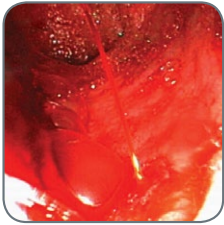


Figure 1

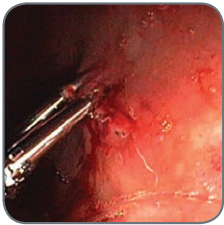

Figure 2

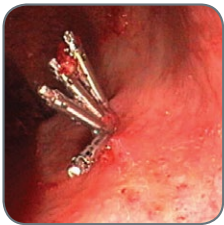

Figure 3

### HISTORY

A 57-year-old male presented 36 hours after colonoscopy with profuse rectal bleeding and hypotension. During the colonoscopy the patient had seven polyps removed by snare, some with and some without cautery. Of note, a 1cm polyp had been removed from the rectum using a snare with cautery.

### PROCEDURE

The patient was admitted to the ICU and blood volume restored. He was given a rapid GoLYTELY™ Solution purge and underwent urgent colonoscopy. During the colonoscopy, large amounts of red blood and clots to the splenic flexure and blood tinged mucosa to the cecum were observed. No active bleeding was noted on withdrawal until reaching the rectum. On the posterior wall of the rectum, at the site of polypectomy, there was a large visible “spurting” vessel that was vigorously bleeding. (Figure 1)

Hemostasis could not be achieved with 10 cc (1:10000) epinephrine or bipolar cautery. Bleeding was largely controlled with the application of the first two Resolution Clips. Subsequently, four Resolution Clips were deployed resulting in complete hemostasis. (Figure 2 & 3) The patient had no further bleeding at the site of the polypectomy and was discharged from the hospital 24 hours later.

*Images provided courtesy of Dr. Komanduri*



## Post-polypectomy Perforation

Case Presented by:

**YOUSIF I. A-RAHIM, M.D., PH.D.**

*Assistant Professor of Medicine, University of Hawaii,*

*John A. Burns School of Medicine, Honolulu, HI*

*Case Performed at: Straub Clinic and Hospital, Honolulu, HI*

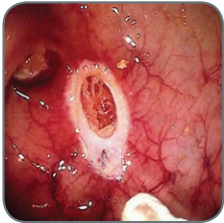


Figure 1

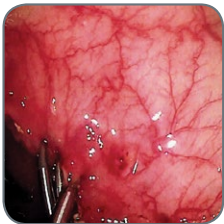


Figure 2

### HISTORY

A 77-year-old female presented with symptomatic rectal bleeding combined with changes in bowel habits. Colonoscopy revealed a 1cm polyp at the splenic flexure. The polyp was removed by snare polypectomy. Post-polypectomy, there was evidence of a cavity at the polypectomy site (Figure 1) where pericolonic fat could be seen, consistent with a perforation.

### PROCEDURE

The perforation was immediately sealed by means of four Resolution Clips (Figures 2 & 3). The colon was then decompressed and the colonoscope was carefully and safely withdrawn. The patient was made NPO and intravenous fluids, nasogastric suction and antibiotics were immediately initiated. The patient experienced mild sharp pain in the left lower quadrant following the procedure. Her vital signs immediately following the procedure were: temp – 99° F, blood pressure – 120/74, respirations – 16 and oxygen saturation at 97% on room air. Her physical examination was remarkable for a mildly tender and distended abdomen without bowel sounds. KUB and upright films were obtained (Figure 4) and showed large pneumoperitoneum and the Resolution Clips at the splenic flexure. The patient was admitted for observation.

### POST PROCEDURE

The patient's bowel sounds returned to normal within a few hours after the procedure. Her abdominal distention was much improved and she was able to pass flatus. Approximately six hours after the procedure, she complained of mild pain in the left lower quadrant that was managed with a single dose of acetaminophen. Over the next 24 hours, she continued to do very well. The next morning, she was afebrile, denied pain and was passing flatus. Her white blood cell count at that time was approximately 6.9 k. Her diet was advanced to full liquids, which she tolerated well.

Forty-eight hours after the event, the patient was still without any abdominal pain and was tolerating the full liquid diet. She began having liquid yellowish bowel movements without any blood and was discharged home on oral antibiotics and a liquids-only diet for the next five days. She was seen in clinic one-week after the complication and a KUB was repeated showing minimal retroperitoneal air, at which time her diet was liberalized.

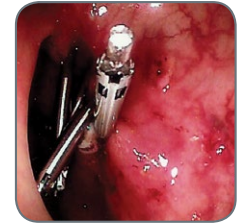

Figure 3

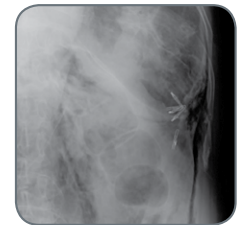

Figure 4

*Images provided courtesy of Dr. A-Rahim*

CASE 21

## Clipping of a Visible Vessel After Initial Hemostasis

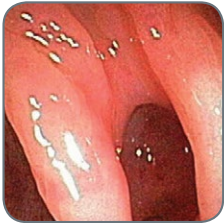

Figure 1

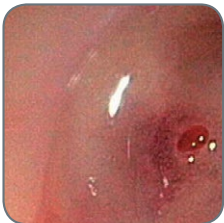

Figure 2

### HISTORY

An 81 year old white male with a history of diverticular bleeding requiring a left hemicolectomy presented with three episodes of hematochezia. Examination revealed a soft, non-tender abdomen. Bright red blood was observed on rectal exam. At presentation, his hemoglobin and hematocrit were 11.6 and 35.3 respectively.

### PROCEDURE

With aggressive fluid hydration a nadir of 7.9 and 23.4 for hemoglobin and hematocrit were reached. Colonoscopy revealed copious amounts of blood in the left side of the colon. Multiple diverticula were found throughout the colon. In the mid-transverse colon, brisk bleeding was observed from one diverticulum (Figure 1). After flushing, hemostasis was achieved with injection of 2 ccs of 1:10,000 epinephrine. Examination of the diverticulum then revealed a raised visible vessel with a blood droplet forming (Figure 2). The Resolution Clip Devices were placed above and below the vessel in the diverticulum to provide tamponade (Figure 3 & 4). The patient received a total of three units of packed red blood cells during his hospital stay and no further bleeding occurred.

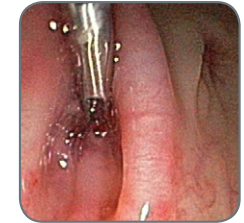

Figure 3

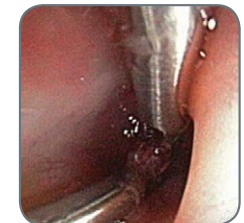

Figure 4

*Images provided courtesy of Dr. Livinghouse*

Case Presented by:

**DAVID G. HEWETT, MBBS, MSC, PH.D., FRACP**

*Associate Professor,  
University of Queensland School of Medicine  
Deputy Director (Endoscopy),  
Queen Elizabeth II Jubilee Hospital  
Brisbane, AUSTRALIA*

CASE 22

## Resolution Clip Devices Closure of Muscularis Propria Injury during Colonoscopic Resection of a Large Serrated Polyp

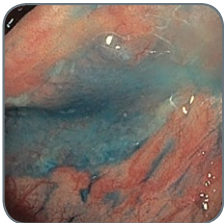

Figure 1

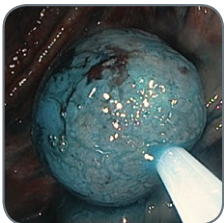


Figure 2

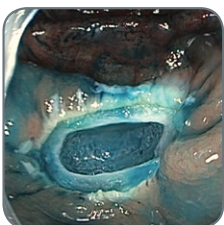


Figure 3

### HISTORY

A 64-year-old female with serrated polyposis syndrome underwent a colonoscopy for endoscopic resection of the large proximal colon sessile serrated adenomas. This was her second colonoscopy for clearance of serrated lesions. Indigocarmine dye spray cap-fitted colonoscopy was used to facilitate detection, and a large sessile serrated adenoma/polyp (SSA/P) was identified at the hepatic flexure (Paris classification 0-IIa, 25mm, Figure 1).

### PROCEDURE

Colonoscopic resection of the 25mm sessile serrated adenoma at the hepatic flexure was performed. An en bloc resection was attempted (Figure 2) following a submucosal injection of succinylated gelatin (Gelifusine™ Expander) mixed with indigocarmine (80mg in 500mL solution), and using electrocautery (ERBE Vio 300D, EndoCut™ Device). Carbon dioxide is used routinely for insufflation. After resection, a large concentric defect (approximately 10-15mm) in the muscularis propria was evident (Figure 3, mirror target sign), with corresponding target sign on the resected specimen (Figure 4, resected specimen ex-vivo, with a central white disk of muscularis propria surrounded by indigocarmine-stained blue submucosal tissue).

The defect was closed using Resolution Clip Devices (Figures 5 and 6). A total of 16 clips were applied sequentially from one side of the defect to the other in a “zipper” fashion. Each clip was placed immediately adjacent to the last to ensure complete closure in case of full thickness perforation.

Sequential clip closure required careful maneuvering of each clip to achieve a satisfactory position and acquire sufficient normal tissue within the clip to tightly appose the defect margins. To achieve closure, one arm of the clip can be used to grasp and lift normal tissue before then angulating the other arm into position on other side of the defect (again grasping a generous amount of normal tissue). Gentle application of suction can help bring the margins together, while minimally advancing the catheter, often with simultaneous down angulation of the instrument tip. Excessive tension on the colon wall from forward advancement of the clip should be avoided (to encourage generous tissue capture within the clip).

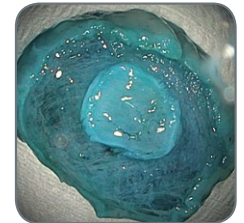


Figure 4

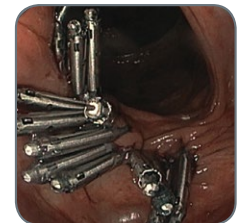


Figure 5

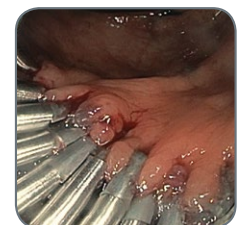

Figure 6

▶ Continued on Next Page

*Images provided courtesy of Dr. Hewett*

Case Presented by:

**DAVID G. HEWETT, MBBS, MSC, PH.D., FRACP**

*Associate Professor,  
University of Queensland School of Medicine  
Deputy Director (Endoscopy),  
Queen Elizabeth II Jubilee Hospital  
Brisbane, AUSTRALIA*

CASE 22 CONTINUED

## Resolution Clip Devices Closure of Muscularis Propria Injury during Colonoscopic Resection of a Large Serrated Polyp

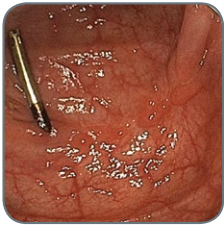

Figure 7

### POST PROCEDURE

Intraoperative intravenous antibiotics were administered, and the patient was admitted to hospital for observation on a clear fluid diet. The patient reported no post-procedure abdominal pain. A CT of the abdomen excluded full thickness perforation, and the patient was discharged within 24 hours. Histology confirmed muscularis propria resection without serosa. Follow-up colonoscopy at four months demonstrated complete resection of neoplastic tissue, with a single clip remaining embedded within the scar (Figure 7).

### CONCLUSIONS

Resolution Clip Devices are effective tools for closure of endoscopic perforations and deep muscle injury. During endoscopic resection, recognition of muscularis propria injury is important, and careful inspection of the base of the specimen (in vivo) and the mucosal defect for target/mirror target signs is essential. Caution with an en bloc resection of >20mm serrated lesions is warranted despite large volume submucosal injection and careful technique.

[◀ Previous Page](#)

*Images provided courtesy of Dr. Hewett*

Home

Esophagus

Stomach/Duodenum

Colon

[◀ Prev Case](#)

[Next Case ▶](#)

Case Presented by:  
**SHIVANGI KOTHARI, M.D.**  
**VIVEK KAUL, M.D., FACG**

Center For Advanced  
Therapeutic Endoscopy  
University of Rochester Medical Center  
Rochester, NY, USA

CASE 23

## Successful Management of Immediate and Delayed Post-polypectomy Bleeding with the Resolution Clip Device

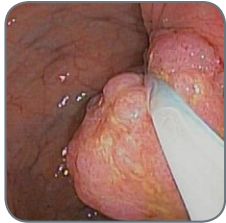

Figure 1

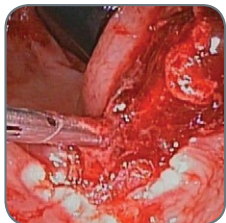


Figure 2

### HISTORY & PROCEDURE

A 61-year-old male with past medical history significant for hypertension and diabetes mellitus was referred for screening colonoscopy (average risk). During colonoscopy, eight 5-6mm polyps were resected and retrieved from the ascending and transverse colon using a hot snare. An approximately 5cm polyp on a short, broad-based stalk measuring about 1.5 cm was seen in the sigmoid colon. EndoLoop™ Ligature was deployed at the base of the polyp and the polyp was resected in a piecemeal manner, in antegrade and retroflexed positions. The polyp base was then elevated with a submucosal saline injection and was resected with snare cautery (Figure 1). Since the stalk was very short and broad based, the base of the polyp with the stalk was resected with the snare below the endoloop to ensure clear margins, and was submitted separately to pathology.

Immediately post-resection, significant brisk bleeding was seen from an arterial vessel in the polypectomy base. Epinephrine (1:10,000 x 20cc total) was injected at the site followed by deployment of eight Resolution Clip Devices (Figure 2). Direct application of the endoclips at the site of arterial bleeding (slightly less than 2mm) was done to achieve hemostasis and approximation of the edges of the 2.5cm resection site also was accomplished. Complete hemostasis was achieved at the end of the procedure (Figure 3). The patient was admitted for overnight observation. He remained stable with no further bleeding and he was discharged home the following day.

### POST PROCEDURE

Two days after the procedure, the patient presented to the emergency room with hematochezia. His hematocrit had dropped from 34 to 31. He was hemodynamically stable. Flexible sigmoidoscopy revealed a small amount of persistent bleeding from the arterial site where one clip appeared to have been dislodged (Figure 4). The remaining endoclips were still in place and there was no bleeding from those parts of the polypectomy site. Epinephrine (1:10,000 x 10 cc) was injected into the bleeding area and two additional clips were placed at the site of bleeding with complete hemostasis at the end of the procedure. The patient remained stable with no further episodes of bleeding. Pathology revealed the

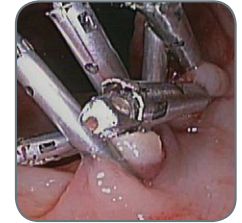


Figure 3

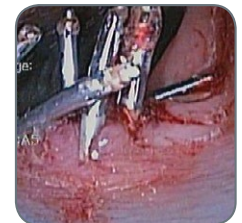

Figure 4

▶ Continued on Next Page

Images provided courtesy of Dr. Kothari and Dr. Kaul



Case Presented by:

**SHIVANGI KOTHARI, M.D.**  
**VIVEK KAUL, M.D., FACG**

*Center For Advanced  
Therapeutic Endoscopy  
University of Rochester Medical Center  
Rochester, NY, USA*

CASE 23 CONTINUED

## Successful Management of Immediate and Delayed Post-polypectomy Bleeding with the Resolution Clip Device

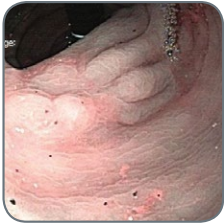

Figure 5

lesion to be a tubulovillous adenoma, completely resected with clear margins. A follow-up colonoscopy was performed three months after the initial procedure and no recurrence or residual adenoma was seen at the resection site or on surveillance biopsies of the healed polypectomy site (Figure 5).

### DISCUSSION

Immediate post-polypectomy bleeding can occur in up to 1.5 to 3 percent of cases. Endoclips are being increasingly used to manage post-polypectomy bleeding. The clip can be placed across the base of the stalk of a pedunculated polyp prior to resection to minimize risk of post-polypectomy bleeding.

In our practice, we are placing endoclips for hemostasis when we feel there is an elevated risk of post-polypectomy bleeding. This could be patients with other co-morbidities and/or coagulopathy, defect sites with exposed blood vessels, or patients on anticoagulation.

When bleeding is encountered after resection of a pedunculated polyp, placing a clip across the stalk can help achieve durable hemostasis. In case of bleeding after resection of sessile polyps, the clip can be placed directly over the bleeding site, as in the above case. Additional clips can be placed to approximate the edges of the resection site in high risk situations, but the benefit of doing that has not been studied in a randomized trial design. Delayed post-polypectomy bleeding can occur from ulceration at the polypectomy site. In our patient, the relatively large caliber of the bleeding vessel, ulceration at the site and possible clip displacement led to recurrent bleeding. However, this was managed successfully with placement of additional endoclips at the site of the bleeding vessel. Our case illustrates successful management of immediate and delayed post-polypectomy arterial bleed with the use of the Resolution Clip Device.

◀ Previous Page

*Images provided courtesy of Dr. Kothari and Dr. Kaul*



Case Presented by:

**TARA CHALMERS-NIXON, M.D., FRCPC**

*Clinical Assistant Professor*

*University of Calgary, Rockyview Hospital*

*Calgary, Alberta, CANADA*

CASE 24

## Polypectomy Using the Interject Needle, Captivator Snare and TWISTER PLUS Rotatable Retrieval Device

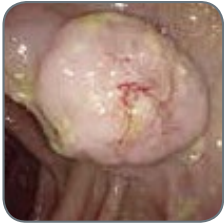

Figure 1

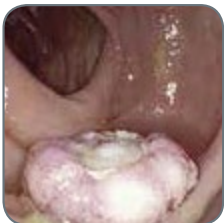

Figure 2

### HISTORY

The patient was a 55-year-old male referred for nonspecific gastrointestinal complaints, including irregular bowel habits and abdominal discomfort. His past medical history was significant for obesity, diabetes, hypercholesterolemia, hypertension and hypothyroidism. He previously had a cholecystectomy. Although his complaints were most likely a result of medication side effects, a colonoscopy was recommended to investigate further. This was the patient's first colonoscopy.

### PROCEDURE

The patient was sedated with midazolam 5mg and fentanyl 50 mcg IV, and monitored with the appropriate monitoring equipment. Using a video colonoscope, the scope was advanced to the ileum. The bowel was well prepared with only clear liquid remaining. A 2.5cm polyp with a central depression was identified 5cm distal to the ileocecal valve. Because of concern for malignancy, the goal was to remove the polyp en bloc. Using an Interject™ Injection Therapy Needle Catheter the polyp was lifted and injected with 10cc of normal saline (Figure 1). The polyp was then removed using a large oval Captivator™ Single Use Snare with cautery applied (Figure 2). It was removed in one piece. The polypectomy site was clean and not bleeding, but rather large and in the proximal colon (Figure 3). As such, I felt that hemostasis was required and decided to close the post-polypectomy defect (approximately 2cm in length and 5-6mm wide) using Resolution Clip Devices.

Three Resolution Clip Devices were placed without difficulty to close the defect. The actual polyp site was in a good position, so the clips deployed very well without any torque applied to the scope, and very little rotation of the clip was needed (Figure 4).

Before this polyp was retrieved, a second 1.0 cm polyp was identified just distal to the first polypectomy, so it was removed also with a snare cautery. Clips were not applied to this second site. Both polyps were then sitting in the lumen of the bowel.

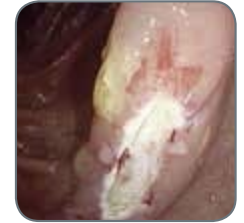

Figure 3

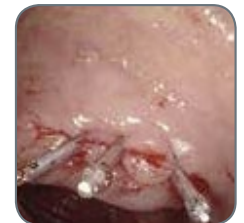

Figure 4

▶ Continued on Next Page

*Images provided courtesy of Dr. Chalmers-Nixon*

Case Presented by:

**TARA CHALMERS-NIXON, M.D., FRCPC**

*Clinical Assistant Professor*

*University of Calgary, Rockyview Hospital*

*Calgary, Alberta, CANADA*

CASE 24 CONTINUED

## Polypectomy Using the Interject Needle, Captivator Snare and TWISTER PLUS Rotatable Retrieval Device

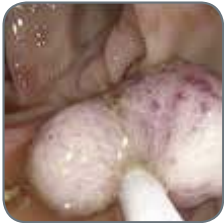

Figure 5

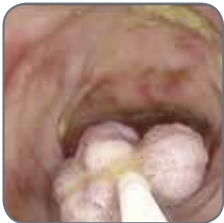

Figure 6

Next, a TWISTER® PLUS Rotatable Retrieval Device was used to grab both of the large polyps together and remove them. The TWISTER PLUS Rotatable Retrieval Device fit around the two polyps without crushing them, allowing for the removal of both in one withdrawal (Figures 5 and 6). The polyps were then sent for pathology. The TWISTER PLUS Rotatable Retrieval Device retrieval net was easy to use and there was excellent visibility of the polyp tissue through the netting. The 'spine' (or third wire) in the TWISTER PLUS Rotatable Retrieval Device may have helped place the net over the polyps.

### OUTCOME

The patient tolerated the procedure well and all the polyps were removed successfully during this single procedure. He had not experienced any post-polypectomy bleeding as discussed during his follow up more than 14 days post procedure. The largest polyp was a villous adenoma with high-grade dysplasia but no cancer. The second smaller polyp was a tubulovillous adenoma. The patient is scheduled for a follow-up colonoscopy within two weeks to be sure of complete removal given the size, pathology and saline lifting of the largest polyp, and to be sure no additional polyps were missed.

### CONCLUSION

Proper polypectomy removal and retrieval is critical to performing a good-quality colonoscopy. Being able to send the polyp for pathological examination determines if the patient will or will not need resection, especially in the case of large polyps with worrisome features such as the one identified in this case: greater than 1cm, central depression, etc. Had it not been possible to remove the polyp and retrieve it properly, the patient may have had to have a resection of the area where the polyp was.

Information and in-services for the physicians and nurses in our endoscopy unit have been very helpful in using all of these Boston Scientific devices in appropriate situations.

[◀ Previous Page](#)

*Images provided courtesy of Dr. Chalmers-Nixon*

Case Presented by:

**RAJESH N. KESWANI, M.D.**  
**DAVID J. BENTREM, M.D., M.S.**

Associate Professors  
Northwestern University Feinberg  
School of Medicine  
Chicago, Illinois, USA

CASE 25

## Endoscopic Mucosal Resection is Used for Polypectomy; Resolution Clips Close the Defect

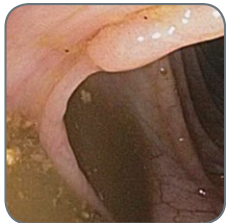

Figure 1

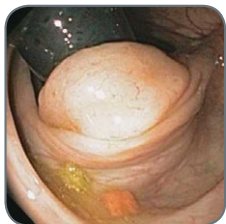

Figure 2

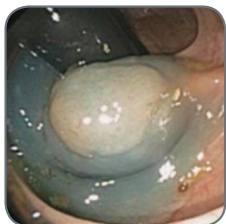


Figure 3

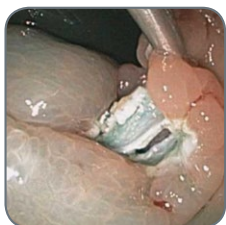

Figure 4

### HISTORY

A 55-year-old female presented for a surveillance colonoscopy to her primary gastroenterologist. During the surveillance colonoscopy, a 25mm non-polypoid (Paris O-Ia) lesion was seen in the mid-ascending colon and was biopsied to be a tubular adenoma (Figure 1). She was referred to a therapeutic endoscopist for an endoscopic mucosal resection (EMR).

### PROCEDURE

As the polyp was predominantly located on a proximal fold of the ascending colon, visualization was best in retroflexion from the cecum (Figure 2). A submucosal lift was achieved with saline mixed with indigo carmine. Excellent lift of the polyp was noted (Figure 3). The majority of the polyp was resected using a polypectomy snare and cutting current.

A 10mm perforation was immediately noted after resection with a “target sign” (linear non-staining of the indigo carmine, Figure 4). As the patient was clinically well, the remainder of the polyp was first removed and then attention was paid to closing the defect. While maintaining scope position, five Resolution Clips were deployed to completely close the perforation (Figure 5). In forward view, three additional Resolution Clips were placed to fully close the remaining post-polypectomy defect (Figure 6).

### POST PROCEDURE

The patient was admitted to the hospital and was made nil per os (NPO) with intravenous antibiotics. Surgical consultation was obtained with an agreement for an attempt at non-operative management. She experienced mild pain that did not require analgesia on the first day.

An abdominal x-ray was obtained on the second day of hospitalization and demonstrated marked free intra-peritoneal air (Figure 7). All eight Resolution Clips remained in place in the ascending colon (Figure 8).

A computed tomography scan with oral contrast was performed on day three and showed no leakage of contrast at the polypectomy site and a slight reduction in intra-peritoneal air. Based on these findings and her clinical wellness, an oral diet was resumed and she was discharged.

*Images provided courtesy of Dr. Keswani and Dr. Bentrem*




Figure 5

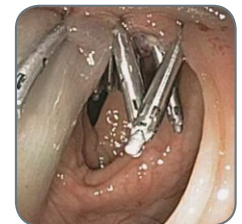

Figure 6

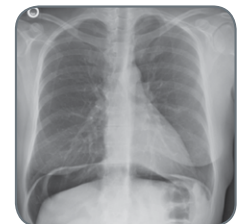


Figure 7

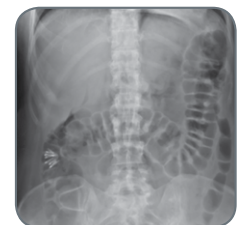

Figure 8

## Endoscopic Mucosal Resection for a Large Polyp Removal

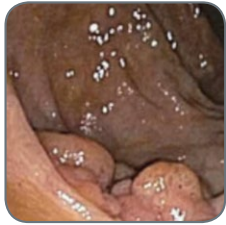

Figure 1

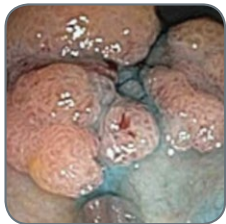


Figure 2

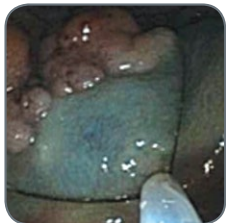


Figure 3

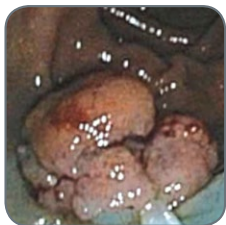

Figure 4

### HISTORY

A 55-year-old male with a prior history of colon polyps underwent a recent colonoscopy, which revealed a 2.5cm flat polyp (Figure 1). Biopsies showed a tubulovillous adenoma. Surgery was recommended but the patient sought a second opinion in regard to endoscopic mucosal resection (EMR).

### PROCEDURE

The patient underwent a repeat colonoscopy with the intent to perform an EMR. As previously noted, the polyp was flat and large. Normal saline was prepared with a few drops of methylene blue added to achieve a light-aqua blue color. Using 20cc of this solution, the polyp was lifted (Figure 2). Following this, a 33mm Captivator™ II Snare was used to grasp the polyp in one piece (Figure 3). Using standard electrocautery settings, the polyp was resected in one piece (Figures 4 and 5). Argon plasma coagulation was then used to cauterize the edges of the polyp so that the chances for regrowth would be diminished (Figure 6). Four Resolution Clips were applied to the resulting mucosal defect, which was approximately 2cm in size (Figure 7). Finally, the polyp was recovered using the TWISTER® PLUS Rotatable Retrieval Device (Figure 8).

### POST PROCEDURE

Following the procedure, the patient did well with no post-polypectomy bleeding or signs of perforation. He was discharged the same day, and a relook endoscopy was done three months later, which showed healing of the polyp site.

### CONCLUSION

Endoscopic mucosal resection is fast becoming the treatment of choice for large polyp resection, and is a good and less expensive alternative to surgery. Because the risk of bleeding was high, I decided to place Resolution Clips. The Resolution Clip is ideal for this scenario due to its 11mm jaw opening and the fact that it can open and close prior to being deployed.

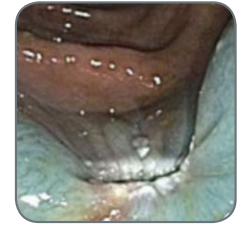

Figure 5



Figure 6

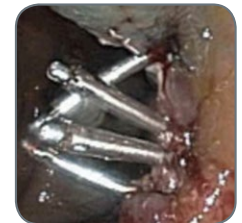

Figure 7

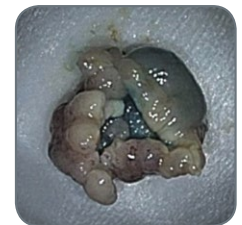


Figure 8

Images proved courtesy of Dr. Sachdev

Results from case studies are not predictive of results in other cases.  
Results in other cases may vary.

All trademarks are the property of their respective owners.

Indications, Contraindications, Warnings and Instructions for Use can  
be found in the product labeling supplied with each device.

**CAUTION: Federal (USA) law restricts this device to sale by or on  
the order of a physician.**

**CAUTION: The law restricts these devices to sale by or on the order  
of a physician. Information for the use only in countries with  
applicable health authority product registrations.**

**Boston  
Scientific**

Advancing science for life™

Boston Scientific Corporation  
300 Boston Scientific Way  
Marlborough, MA 01752  
[www.bostonscientific.com/endo-resources](http://www.bostonscientific.com/endo-resources)

**Ordering Information**  
**1.888.272.1001**

©2015 Boston Scientific Corporation  
or its affiliates. All rights reserved.

ENDO-270711-AA February 2015