




Technique Spotlight

ERCP with Plastic Stent Placement Sumit Singla, MD, FASGE

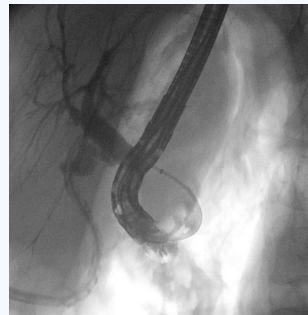
Chief- Gastroenterology and Hepatology
Director of Endoscopic Services
Senior Staff, Advanced Therapeutic Endoscopy

Dr. Sumit K Singla, MD is a paid consultant of Boston Scientific Corporation.



Patient History and Assessment

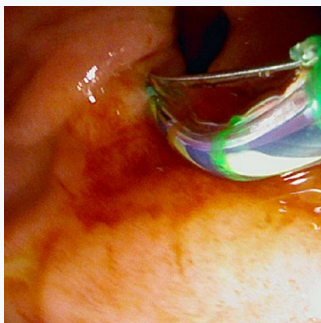
64 year old female with an ampullary diverticulum and a history of post-cholecystectomy bile leak.



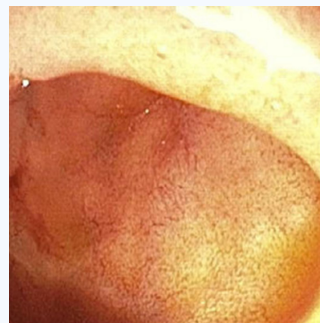Brisk post-cholecystectomy leak

Procedure Plan

Beginning the procedure with a reusable duodenoscope, initial attempts to locate the major papilla were unsuccessful due to inability to reduce the endoscope into the diverticulum.



Successful location and cannulation after switching to EXALT D



Inability to Locate the Ampulla prior to EXALT D

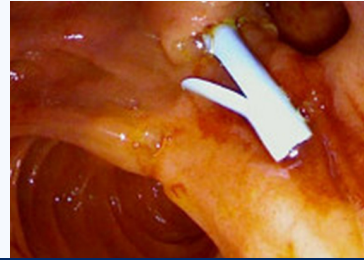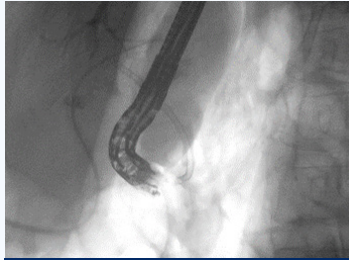
Procedure/ Techniques Used

Dr. Singla switched to EXALT D which offered maneuverability in a situation that required the scope to fit and maintain position in a diverticulum. With this, he had the visual quality necessary to visualize the ampulla hidden in a diverticulum. He was able to gain access with successful cannulation and placed a stent for the active leak.

Case Outcome and Discussion

Results:

The patient's drain output improved, and she was discharged home for outpatient surgical and endoscopic follow up. The patient will come back in a few weeks to remove the stent and perform another ERCP to confirm that the leak has healed.



Post procedure- Biliary Stent in Place

IMPORTANT INFORMATION: These materials are intended to describe common clinical considerations and procedural steps for the use of referenced technologies but may not be appropriate for every patient or case. Decisions surrounding patient care depend on the physician's professional judgment in consideration of all available information for the individual case. Boston Scientific (BSC) does not promote or encourage the use of its devices outside their approved labeling. Case studies are not necessarily representative of clinical outcomes in all cases as individual results may vary.

This case study was produced in cooperation with Dr. Sumit K Singla.

Caution: U.S. Federal law restricts this device to sale by or on the order of a physician.

Images provided courtesy of Dr. Sumit K Singla.

All trademarks are the property of their respective owners.

2024 Copyright © Boston Scientific Corporation or its affiliates. All rights reserved.

ENDO-1931002-AA

**Boston
Scientific**
Advancing science for life™

Boston Scientific Corporation
300 Boston Scientific Way
Marlborough, MA 01752-1234
www.bostonscientific.com