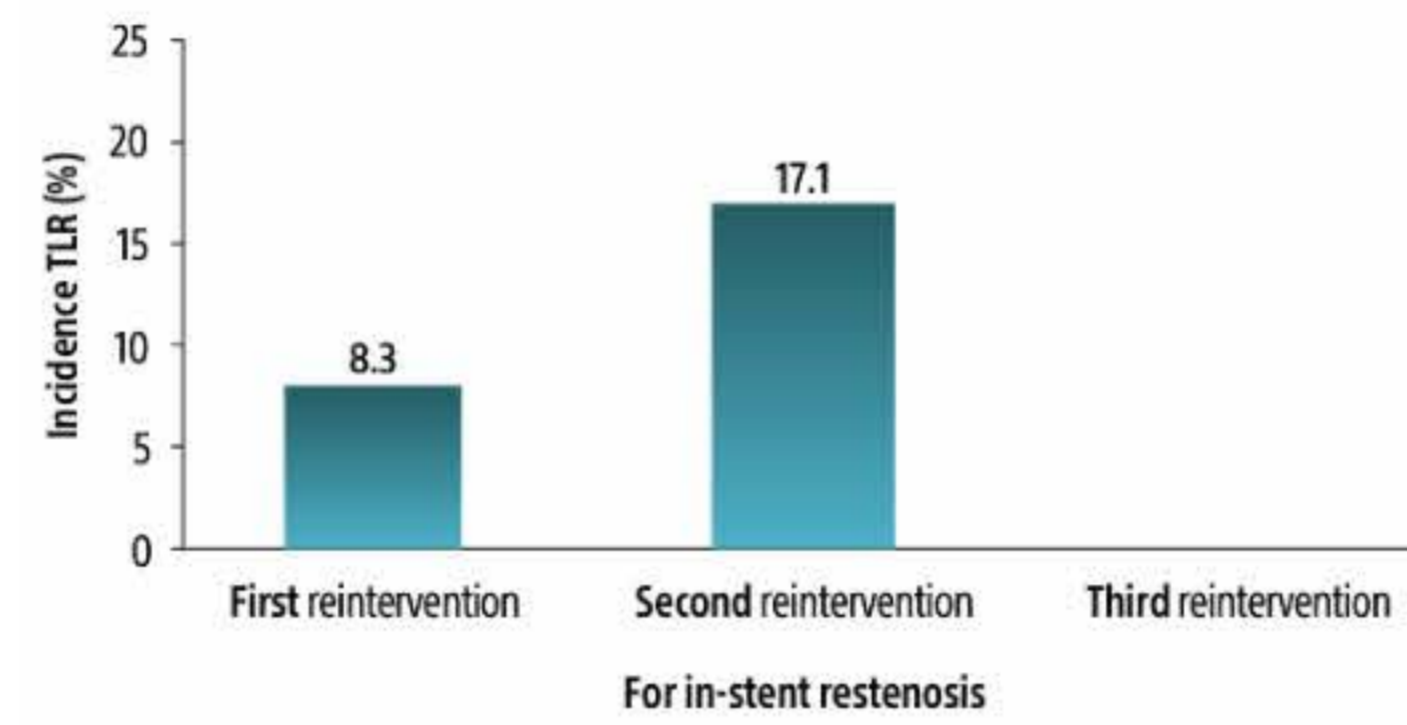


A Global Standard of Care. Now in the U.S.

Drug-coated balloons (DCBs) have been used to treat more than 1 million patients and are considered a global standard of care for in-stent restenosis (ISR) treatment.¹ Approximately 10% of PCIs are complicated by ISR.² Currently, 82% of patients with ISR receive another stent,² which brings increased risks including thrombosis³ and future ISR.^{4,5} DCBs are a proven alternative. This compelling evidence underlines the potential of DCBs in reducing ISR and improving patient outcomes.



Repeat intervention associated with higher risk of target lesion revascularization for ISR¹



Discover DCBs



Boston Scientific

300 Boston Scientific Way | Marlborough, MA 01752-1234

www.bostonscientific.com | 1.888.272.1001

© 2024 Boston Scientific Corporation or its affiliates. All rights reserved.

All trademarks are the property of their respective owners.

If you no longer wish to receive promotional emails from us, [click here](#) to unsubscribe or update preferences.

To read our privacy policy, [click here](#)

IC-1919403-AA

1. Kastrati A, Cassese S (2020). In-stent restenosis in the United States: Time to enrich its treatment armamentarium. In (vol. 76, pp. 1532–1535); American College of Cardiology Foundation, Washington DC

2. Moussa ID, Mohanane D, Saucedo J, et al. Trends and outcomes of restenosis after coronary stent implantation in the United States. J Am Coll Cardiol. 2020;76:1521–1531.

3. Tepe G, Brodmann M, Micari A, et al. 5-year outcomes of drug-coated balloons for peripheral artery in-stent restenosis, long lesions, and CTOs. JACC Cardiovasc Interv. 2023;16:1065–1078.

4. Kawamoto H, Ruparella N, Latib A, et al. Drug-coated balloons versus second-generation drug-eluting stents for the management of recurrent multilayered in-stent restenosis. JACC Cardiovascular Interv. 2015;8:1586–1594.

5. Yabushita H, Kawamoto H, Fujino Y, et al. Clinical outcomes of drug-eluting balloon for in-stent restenosis based on the number of metallic layers. Circ Cardiovasc Interv. 2018;11:e005935.