

Uncovered Ultraflex Stent Use in Upper Tracheal Extrinsic Compression Guided by EBUS



Erik Folch, MD, MSc

Division of Thoracic Surgery and Interventional Pulmonary,
Beth Israel Deaconess Medical Center, Harvard Medical School
Boston, Massachusetts

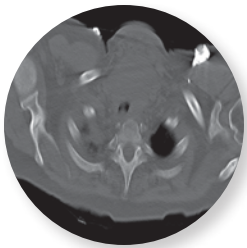


Figure 1

CT Chest with anterior mediastinal mass

Patient History

67-year-old woman with history of non-small cell lung cancer underwent right upper lobectomy 7 months prior to admission. She presented to ER with increasing shortness of breath and stridor. A 7.6 x 5.5 x 6.2 cm anterior mediastinal mass was identified on CT scan (**Figure 1**). She underwent placement of an esophageal stent in the airway that rapidly migrated to the carina and had to be removed. The decision to transfer to our center was made. She arrived intubated with a wire-reinforced endotracheal tube (ETT). (**Figure 2**)

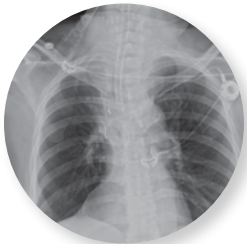


Figure 2

CXR with wire-reinforced ETT

Procedure

On arrival, the patient was taken to the operating room, and under general anesthesia, the ETT was exchanged for a rigid bronchoscope. The EBUS scope was used to determine the upper and lower margins of the tumor as well as to confirm the malignant nature of the anterior mediastinal mass. Thereafter, an 18 x 40mm uncovered Ultraflex stent was placed in the upper trachea and once the position below the subglottis and extending below the lower margin of the tumor was confirmed, it was balloon-dilated in place with a CRE™ Balloon 15-16.5-18. The distal end of the stent clearly bypassed the distal end of the mass as visualized under ultrasound. (**Figure 3**)


Post Procedure

The patient was successfully extubated after the procedure and the diagnosis of metastatic adenocarcinoma was confirmed. She underwent palliative radiation for 6 weeks. Her shortness of breath improved dramatically, and her dry cough is now intermittent but tolerable. She continues to live independently with her family.

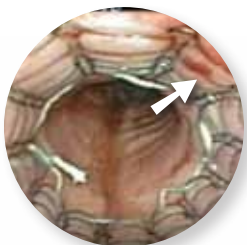

Figure 3

Ultraflex Stent extending beyond the EBUS puncture site (arrow)



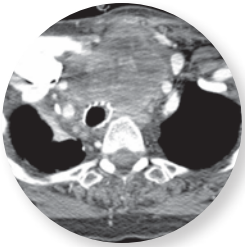
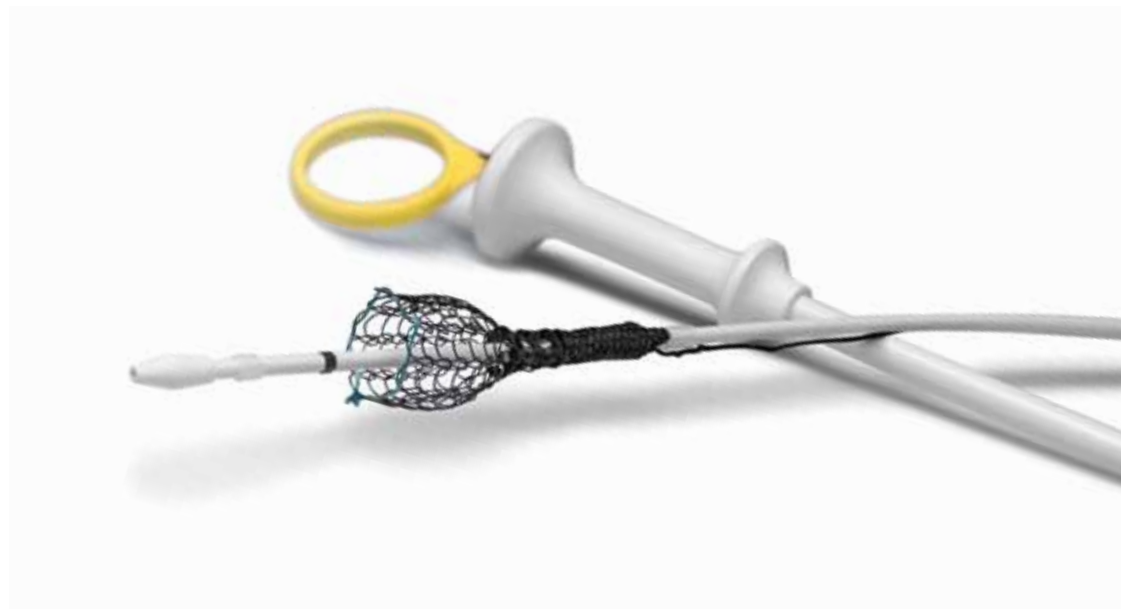

Figure 4
Ultraflex Stent maintaining airway patency despite the pressure of a large anterior mediastinal mass

Discussion

This case demonstrates the difficulty encountered with large anterior mediastinal tumors, where a tracheostomy or external fixation of silicone stents would require percutaneous invasion of the mass with its related possible complications. In this case, a self-expanding metallic stent (Ultraflex) is the best option. Two of the risks involved are migration and shifting of the stenosis point. These were addressed by appropriate sizing with the CRE™ Balloon, using EBUS to delineate the proximal and distal ends of the tumor, and confirming that the stent completely covers the surface area of tumor involvement. **(Figure 4)**



Boston Scientific
Advancing science for life™

Boston Scientific Corporation
One Boston Scientific Place
Natick, MA 01760-1537
www.bostonscientific.com/endo-resources

Ordering Information
1.888.272.1001

©2013 Boston Scientific Corporation or its affiliates. All rights reserved.

ENDO-140704-AA February 2013

Results from case studies are not predictive of results in other cases. Results in other cases may vary.
CRE and Ultraflex are registered or unregistered trademarks of Boston Scientific Corporation or its affiliates.
Indications, Contraindications, Warnings and Instructions for Use can be found in the product labeling supplied with each device.
CAUTION: Federal (USA) law restricts this device to sale by or on the order of a physician.