


# Using the SpyGlass System for the Detection of Unsuspected Intraductal Papillary Mucinous Neoplasm With Main Duct Involvement



CASE PRESENTED BY:

**CARLOS MICAMES CÁCERES, M.D.**

Hospital Bella Vista  
Mayagüez, Puerto Rico, USA

## PATIENT HISTORY

A 61-year-old male was initially referred for evaluation of significant weight loss and pancreatic cysts seen on CT and MRI. An endoscopic ultrasound revealed a 2.1cm cyst in the pancreatic body and mild dilation of the main pancreatic duct measuring 4.1mm in the head and 4.5mm in the genu (**Figure 1**). A fine needle aspiration was performed using a 22ga needle via a transgastric approach. Cytology revealed abundant mucin and cells with vague papillary projections and cytoplasmic vacuoles suspicious of a mucinous cystic neoplasm. The fluid CEA level was 76.8ng/mL.

## PROCEDURE

Due to the patient's significant weight loss and concern for an underlying malignancy, an ERCP was performed. The pancreatic orifice of the major papilla was gaping and extruding mucin (**Figure 2**). The pancreatic duct was cannulated using a sphincterotome and 0.035" guidewire. Pancreatogram revealed that a cystic lesion was infiltrating and branching off the main pancreatic duct at the level of the body (**Figure 3**). A pancreatic sphincterotomy was performed and direct visualization using the SpyGlass® Direct Visualization System revealed papillary projections in a "fish egg" configuration along the main duct at the level of the body extending for approximately 0.5 cm towards the genu (**Figures 4 and 5**). Biopsies taken using the SpyBite® Biopsy Forceps under direct pancreatoscopic visualization confirmed the presence of main duct intraductal papillary mucinous neoplasm (IPMN).

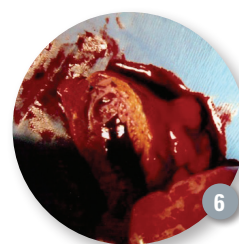
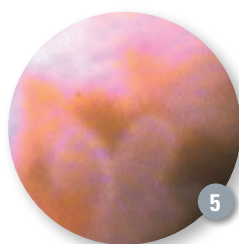
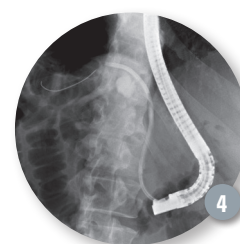
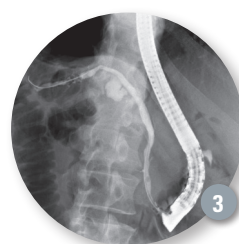
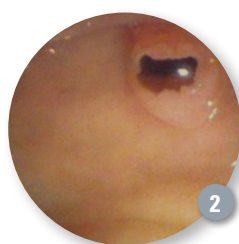
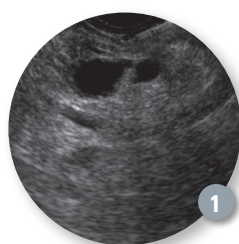
## Intraductal Papillary Mucinous Neoplasm

### OUTCOME / POST PROCEDURE

The patient underwent a distal pancreatectomy with resection of the pancreatic body and tail (**Figure 6**). Pathology revealed a mixed-type IPMN with moderate dysplasia and negative surgical margins. The patient has remained asymptomatic and without evidence of recurrence after more than three years of follow up.

### CONCLUSION

This case illustrates the advantages of direct visualization by performing pancreatoscopy using the SpyGlass System. In addition, intraductal tissue sampling using the SpyBite Biopsy Forceps confirmed the presence of main-duct IPMN, which was previously unsuspected. Surgical resection is recommended in main-duct IPMN due to its high incidence of malignancy. Therefore, accurate identification of IPMN with main duct involvement, such as in this case, is required to determine the need for surgical resection, to serve as a guide for surgical resection, and to prevent progression to adenocarcinoma, a mostly lethal disease.



ACCESS Magazine was produced in cooperation with several physicians. The procedures discussed in this document are those of the physicians and do not necessarily reflect the opinion, policies or recommendations of Boston Scientific Corporation or any of its employees.

Results from case studies are not predictive of results in other cases. Results in other cases may vary.

**CAUTION:** The law, including Federal (USA) law, restricts these devices to sale by or on the order of a physician. Indications, contraindications, warnings and instructions for use can be found in the product labeling supplied with each device.

SpyGlass and SpyBite are registered or unregistered trademarks of Boston Scientific Corporation or its affiliates.

©2012 Boston Scientific Corporation or its affiliates. All rights reserved.

ENDO-101313-AA September 2012