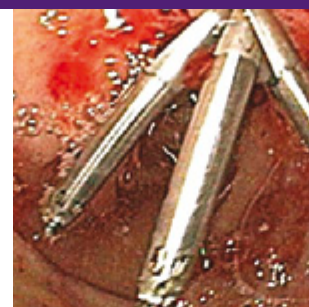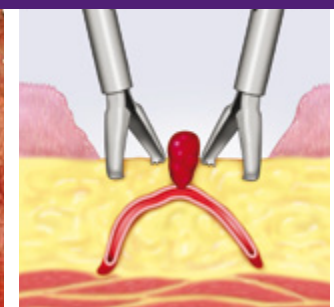
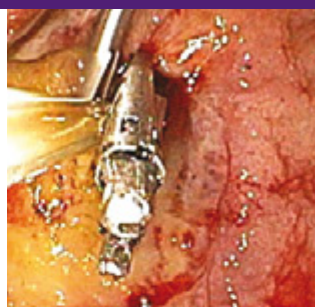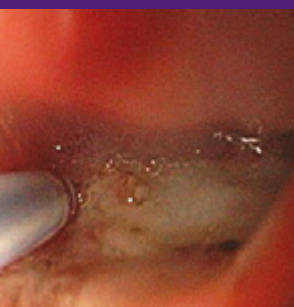


HEMOCLIP: GUIDELINES & ATLAS



Cases presented by: **Dennis M. Jensen, MD**, CURE DDRC, UCLA & VA Medical Centers, and David Geffen School of Medicine at UCLA

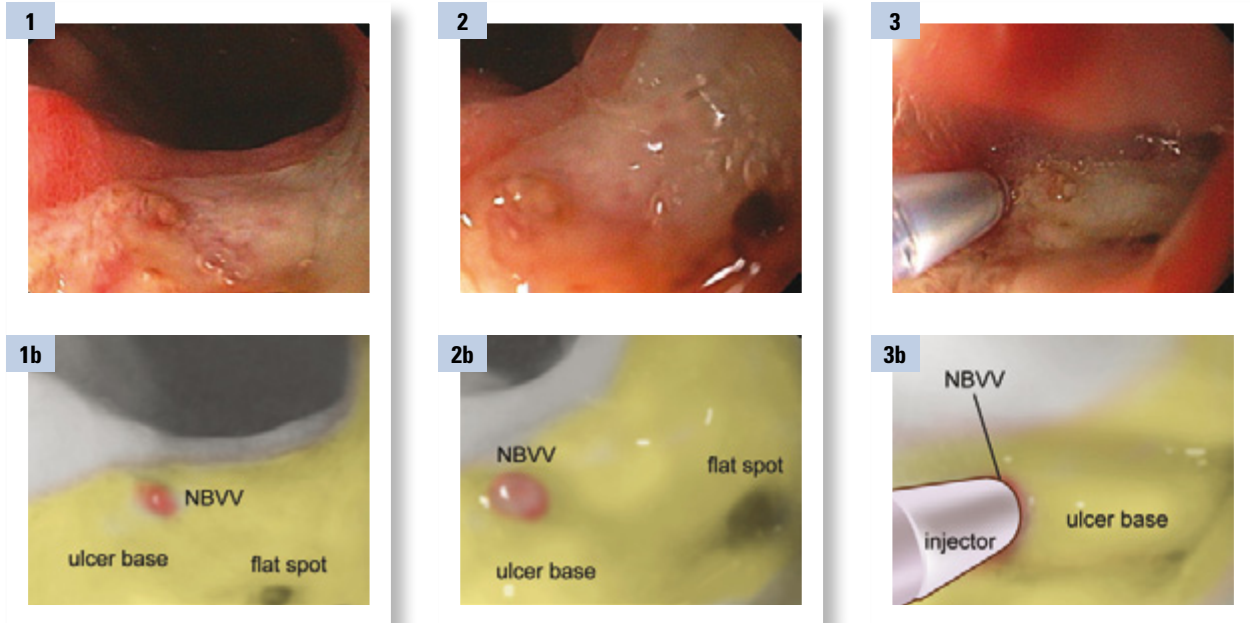
- 1** Epi Injection and Hemocclipping of Chronic Gastric Ulcer (GU) with Non-Bleeding Visible Vessel (NBVV)
- 2** Injection-Hemocclipping of a Bleeding Gastric Ulcer (GU)
- 3** UGI Case – Epi Injection & Hemocclipping of 2 Bleeding Mallory Weiss Tears
- 4** UGI Case – Doppler Probe, Injection & Hemocclipping of Giant Duodenal Ulcer (DU)
- 5** UGI Case – Hemocclipping of Polypectomy Sites
- 6** Colon Case – Sigmoid TIC with NBVV (pulsatile), Doppler Ultrasound Probe (DUP), Hemostasis (Epi Inj + clipping) & Tattoos
- 7** Colon Case – Injection-Hemoclip of Focal Ischemic Ulcer with Recurrent Inpatient Hematochezia
- 8** Colon Case – Spurting Rectal Ulcer: Hemostasis with Injection-Hemocclipping

Case 1:

Epi Injection and Hemoclippping of Chronic Gastric Ulcer (GU) with Non-Bleeding Visible Vessel (NBVV)

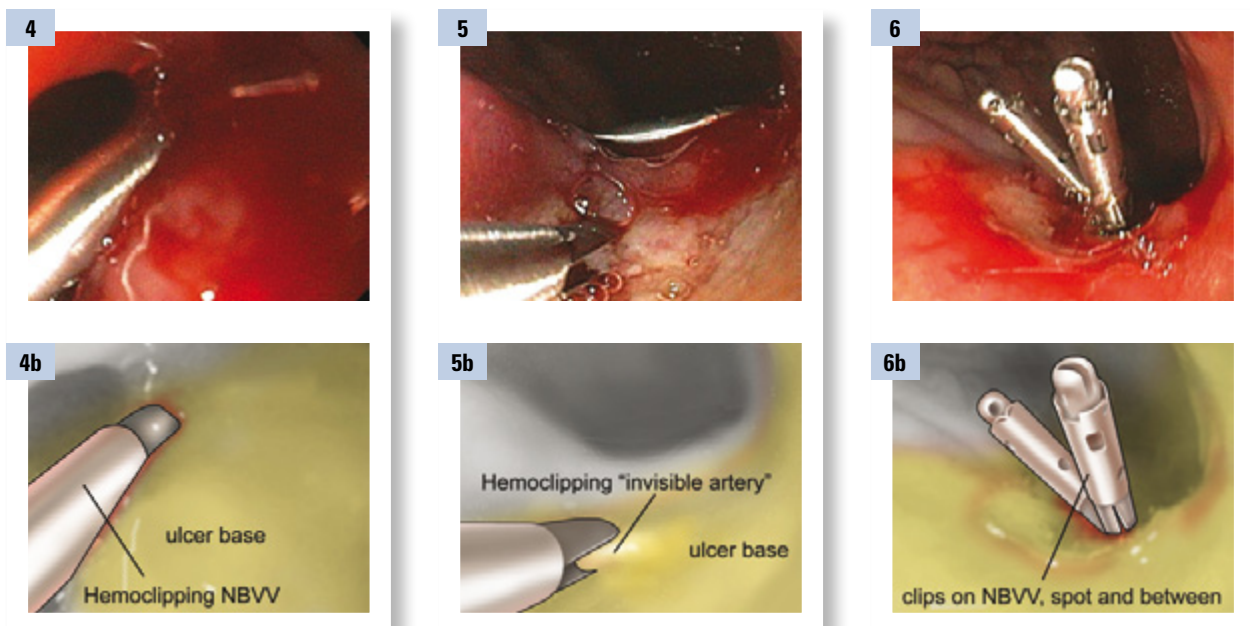
Case presented by: **Dennis M. Jensen, MD**, CURE DDRC, UCLA & VA Medical Centers, and David Geffen School of Medicine at UCLA

72-year-old Asian American male with melena and syncope at home. His co-morbidities are coronary artery disease, hypertension and osteoporosis. He is on aspirin (ASA, acetylsalicylic acid) 325 mg/d and Actinal and drinks 3-6 beers a day. Nasogastric (NG) tube had dark clots. The hemoglobin (Hgb) was 14, but dropped from 9.3 to 8.6 in ER. After resuscitation and transfusion of 2 units of red blood cells (RBCs), the patient had an emergency endoscopy. Our differential diagnosis included peptic ulcer disorder (PUD), gastric cancer or less likely varices (related to the heavy drinking).



Based upon visual criteria, only the non-bleeding visible vessel (NBVV) (in the 9 o'clock position) would be treated endoscopically. There was a flat spot (in the 3 o'clock position) across from the NBVV. However, based upon endoscopic doppler ultrasound probe (DUP), there was superficial arterial blood flow, running between the NBVV and spot about 10 mm apart in the ulcer base. Therefore, the endoscopist should treat the NBVV, the spot, and the artery in between with endoscopic hemostasis (Figures 1-3).

Since the DUP probe was positive for an arterial signal under both the NBVV and the flat spot and also between them, endoscopic treatment of all three areas was indicated. Combination injection and hemoclippping were performed. This is illustrated starting on the top left of the figure and moving left to right, showing the stigmata of recent hemorrhage (SRH) and the epinephrine injection.



Endoscopic treatment was done with combination injection of dilute (1:20,000 in saline) and hemoclippping (Resolution™ Clip, BSC). After DUP, 4 injections (1cc/injection) of dilute epinephrine were placed directly under and between the spot and NBVV. Then the hemoclippping was performed, as shown in Figures 4-6. Three hemoclips (HC) were successfully



placed in the ulcer base, one on each SRH and 1 in between. The ulcer base was fibrotic. Afterward, the DUP was repeated and was negative for underlying blood flow beneath the spot, NBVV, and between them. Biopsies were taken of the antrum and midbody greater curvature for Helicobacter (H) pylori.

This patient was treated with a proton pump inhibitors (PPI) twice a day after discharge from the hospital. He was restarted on 81 mg/day of aspirin for coronary prophylaxis 4 days after his bleed. His H. pylori status was negative by rapid urease test, Giemsa stain, and serology. He had no further UGI hemorrhage and returned for an outpatient endoscopy 5 weeks after the index EGD (and hemostasis). His ulcer was healed and there was a long linear ulcer scar (Figure 7). There was an appearance of chronic gastritis which was confirmed by biopsy (Figure 8). The recommendation was made for the patient to stay on PPI twice a day orally as long as he remained on aspirin. A low dose of aspirin (81 mg) was recommended. These were to prevent ulcer recurrence and rebleeding.

Q&A with Dr. Jensen

Why did you decide to treat?

A: Patient had a high clinical risk of ulcer rebleeding based on comorbidities, ulcer size (large), and presence of 2 stigmata of hemorrhage (NBVV & spot). DUP also revealed an artery coursing between the spot and NBVV with blood flow.

Why did you inject first?

A: Dilute epinephrine reduces blood flow & iatrogenic bleeding caused by touching the NBVV, spot, or artery in between during hemoclipping.

Once injected, why clip?

A: Epinephrine provides only temporary reduction in arterial blood flow in such patients and not permanent hemostasis. Hemoclipping or thermal coagulation can coapt the underlying artery and provide definitive hemostasis.

How do you clip?

A: Grasp tissue in the ulcer base and on each side of the stigmata for visible vessels and in addition on top of the arterial bleeding point first, if present. For chronic ulcers try to place as firmly & deep as possible across the stigmata.

Where do you start injecting and where do you place the clip and why?

A: Pre-inject around stigmata about 0.5 – 1cc / injection x2-3. Place hemoclips (HC) close to (1-2 mm away) but on each side of the non-bleeding stigmata (to occlude the underlying artery) in ulcer base to firmly grasp it. For active arterial bleeding after pre-injection with dilute epinephrine (1:20,000 in saline), first place a clip on top of the bleeding point to stop the bleeding and then one just adjacent (1-3 mm away) on an angle to occlude the underlying artery (as shown in the figure). Or use multipolar electrocoagulation (MPEC) directly & firmly on NBVV. (see Figures 9-11 below)

How do you know when you are done clipping and no further treatment is needed?

- A:** 1.) Stigmata and ulcer base are firmly grasped or well coagulated; there is no bleeding
2.) With Doppler probe (if available) underlying blood flow is halted.

How do you measure success?

A: No rebleeding clinically. No complications.

Is there any follow-up necessary following clipping a NBVV?

A: No. EGD in 6-8 weeks in gastric ulcer (GU) to document healing & exclude cancer with biopsies.

How do you recognize NBVV?

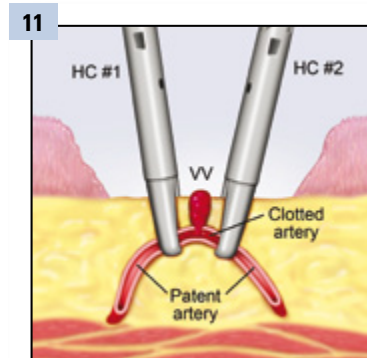
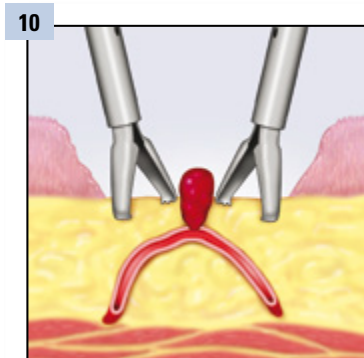
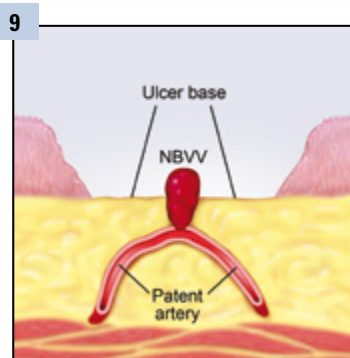
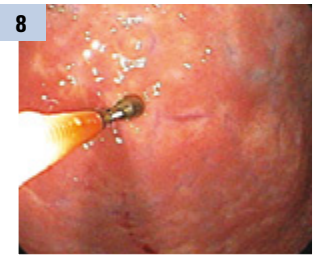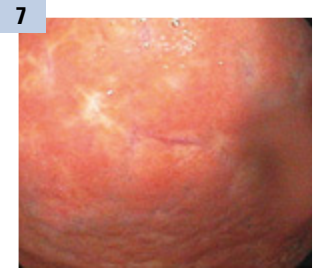
A: As a discrete small (< 5mm usually), raised, smooth protuberance in an ulcer crater. Distinct from a spot which is flat & from a clot that is amorphous & larger (> 6mm).

Why is it important to treat?

A: Rebleed rates of NBVV average risk patients on usual medical therapy are 40-50% & for high risk patients are 50-60%. Endoscopic treatments significantly reduce rebleeding.

Different Grades? If yes, would you treat each differently?

A: No, different grades of NBVV, only higher risk of rebleeding based on ulcer characteristics (deep or size > 2cm) & clinical risk factors. Colors vary from red to black to translucent.



Case 1: Epi Injection and Hemoclipping of Chronic Gastric Ulcer (GU) with Non-Bleeding Visible Vessel (NBVV)



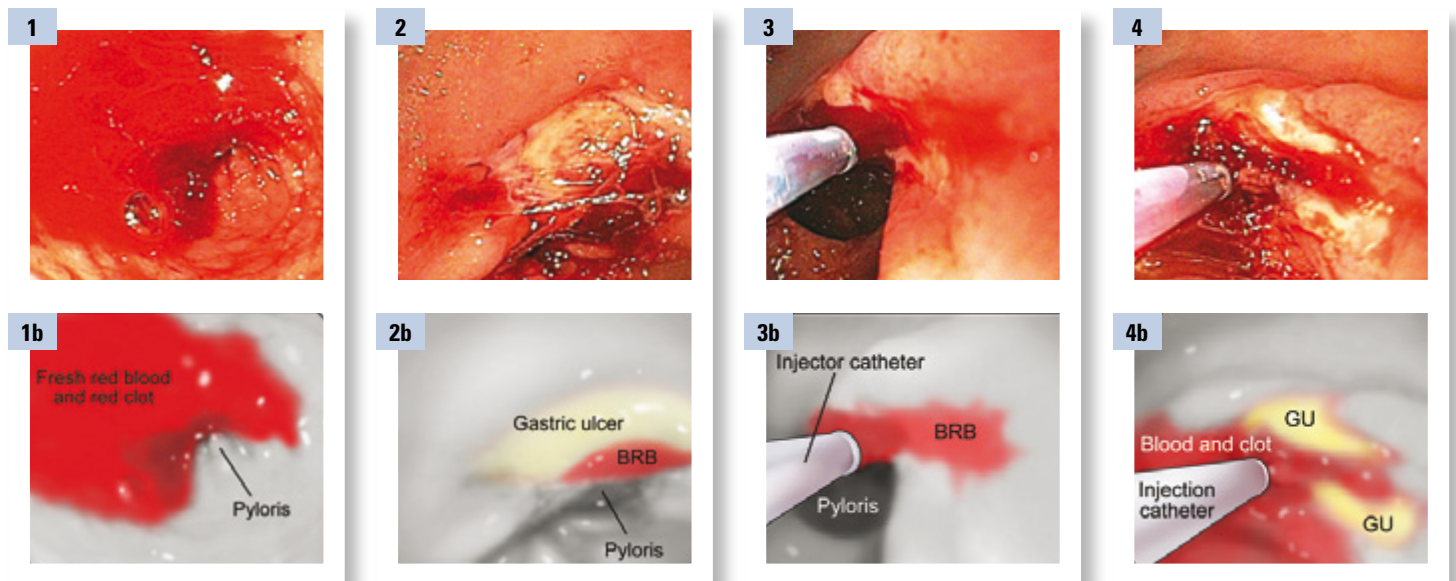
Case 2:

Injection-Hemoclipping of a Bleeding Gastric Ulcer (GU)

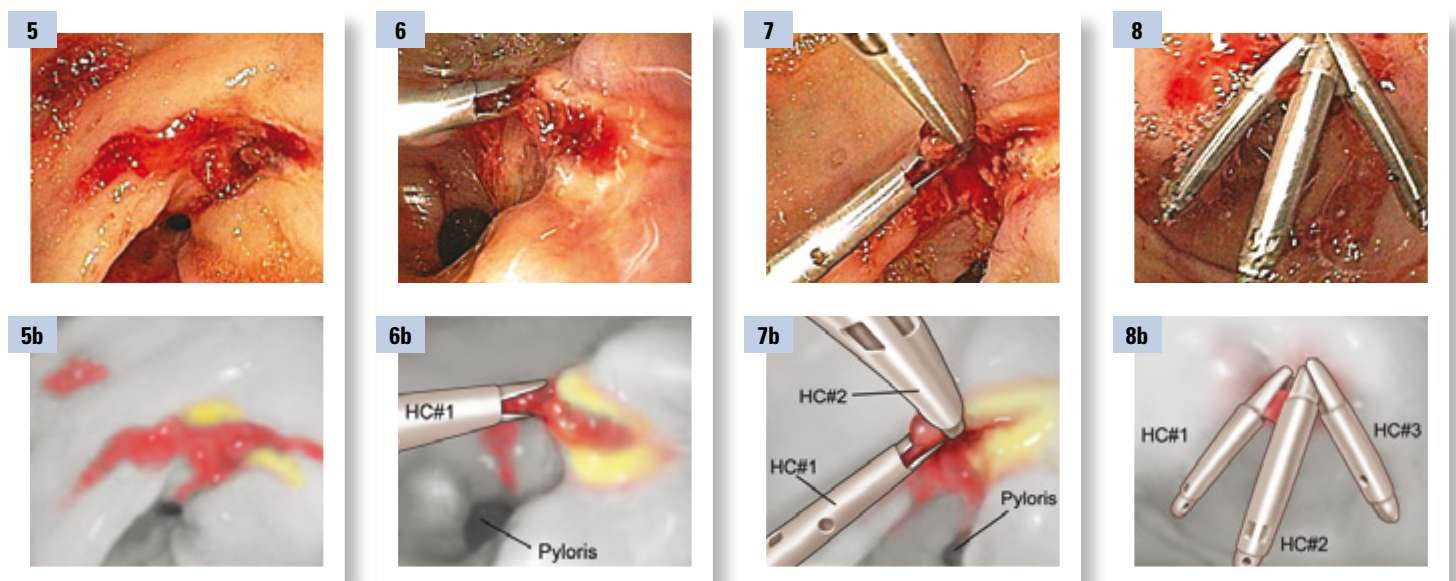
Case presented by: **Dennis M. Jensen, MD**, CURE DDRC, UCLA & VA Medical Centers, and David Geffen School of Medicine at UCLA

23-year-old white male with a previous heart transplant 4 years ago was hospitalized 5 days ago for congestive heart failure, organ rejection, and chronic renal insufficiency. He developed inpatient melena & a hemoglobin (Hgb) drop of 4 gms. His hypotension was treated with pressors to support his blood pressure. A nasogastric (NG) lavage showed coffee grounds. He was transfused 4 units of red blood cells (URBC) and the GI consult service was called.

This patient was on immunosuppressants and hemodialysis and had several severe comorbid conditions, in spite of his young age. These were poor prognostic features as was his inpatient start of UGI hemorrhage. As the cause of the bleeding, we suspected a silent peptic ulcer, rather than infectious ulcer, Mallory Weiss tear, or malignancy. He was not on a PPI before hospital admission. After resuscitation with a total of 6 units of red blood cells (URBC's) and platelets (2 packs), an emergency EGD was performed.



Fresh red blood was found in the antrum on emergency EGD (Figure 1). With target jet irrigation, pulsatile arterial bleeding was seen from the base of a pre-pyloric gastric ulcer (Figures 2-3). This was initially treated with epinephrine injection (1:20,000 in saline) in 4 quadrants (1 cc/injection) around the bleeding point (Figures 3-4). This controlled the arterial bleeding and allowed us to visualize the large chronic ulcer (Figure 4).



With the large pre-pyloric ulcer not actively bleeding, our goals were first to hemoclip (Resolution™ Clip) the focal area that had arterial bleeding before the epinephrine injection (Figures 5 and 6), and then to appose the sides (or close the ulcer crater). Refer to Figures 7-8 for the closure of the ulcer. In order to orient a hemoclip on the bleeding point and other hemoclips (HC) across the ulcer, opening and closing of them and repositioning were required. Subsequently biopsies were taken of the antrum and mid-body greater curvature for H. pylori rapid urease testing and histopathology.



Follow-up

This high risk patient was treated with high dose IV proton pump inhibitors (PPI) (bolus and infusion) for 72 hours. He then continued on oral PPI. After conscious sedation wore off, his diet was advanced to full liquids for 24 hours and then a regular diet. His H. pylori biopsies were negative and there was no rebleeding. The ulcer was documented to heal at 6 weeks on a repeat endoscopy.

Q&A with Dr. Jensen

Why did you inject first?

A: We injected epinephrine first to slow down the arterial bleeding in order to see better and be able to apply the hemoclip to the bleeding artery. Visualization of the bleeding point is critical for accurately targeting hemostasis of non-variceal bleeders.

Once injected, why clip?

A: Epi injection only provides temporary hemostasis particularly for ulcers with spurting arterial bleeding. Some vasoconstriction and tamponade are provided by the epi injection but this is temporary. Permanent hemostasis of ulcers with major stigmata of hemorrhage requires coaptation of the underlying artery either by hemoclipping or thermal techniques. Meta analyses have shown that either hemoclipping or thermal coagulation of major stigmata of ulcer hemorrhage is superior to epi alone.

How do you clip?

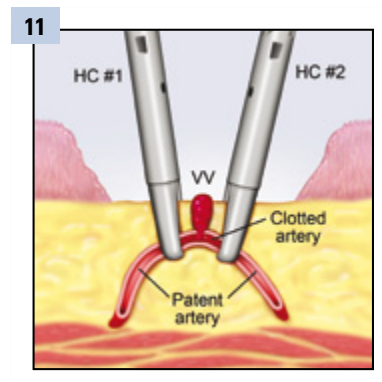
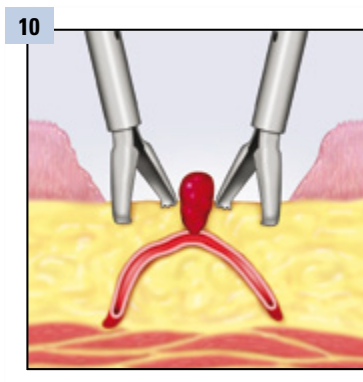
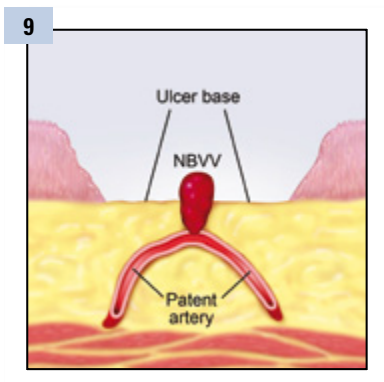
A: Placement of the clip across the bleeding point is very similar to placement of the clip across the non-bleeding visible vessel (NBVV). We know when the clip is in the right place because all of the bleeding stops. If it doesn't then you need to reposition the clip or put another one on (Figures 9-11).

How do you know when you are done?

A: You know when you are done when the bleeding has stopped and the hemoclip or clips are firmly attached to the tissue around the bleeding point. If you have a Doppler ultrasound probe available, an additional confirmation of hemostasis is that the underlying blood flow is absent.

Is there any follow-up necessary?

A: Clinical follow-up is always necessary. In patients with gastric ulcers, we always perform an endoscopy in 6 to 8 weeks after a course of PPIs to document healing. In patients with duodenal ulcers (DUs) we usually only do an endoscopy in case of rebleeding and do not routinely perform an endoscopy at 6 to 8 weeks to document DU healing.



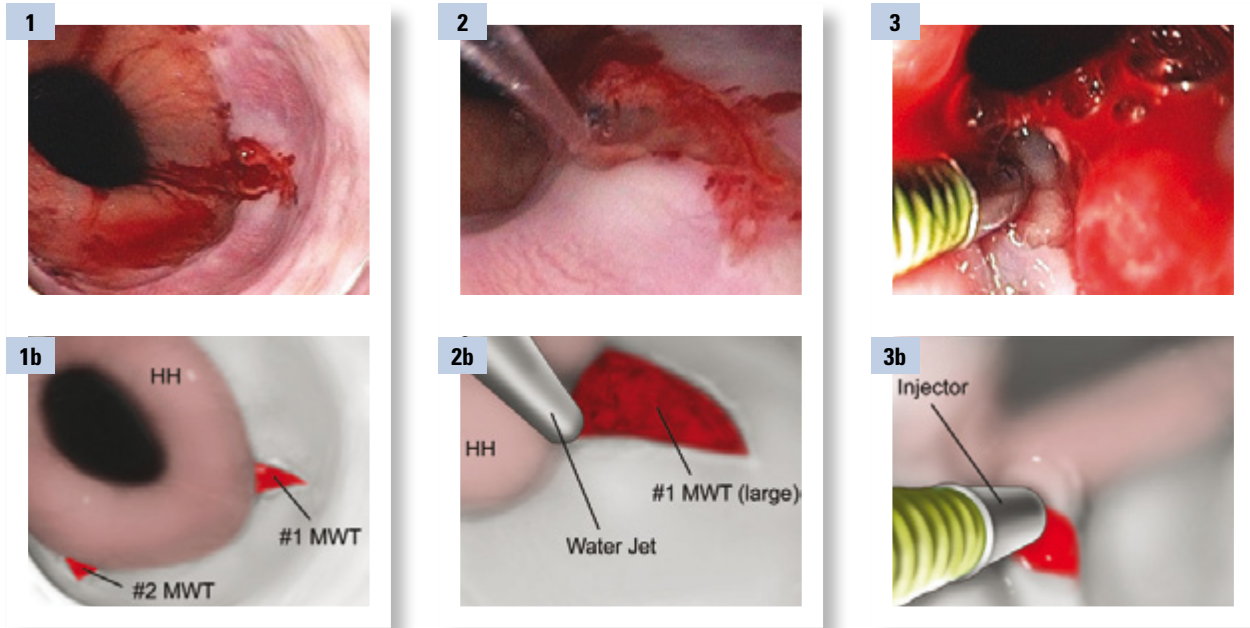
Case 3:

UGI Case – Epi Injection & Hemoclipping of 2 Bleeding Mallory Weiss Tears

Case presented by: **Dennis M. Jensen, MD**, CURE DDRC, UCLA & VA Medical Centers, and David Geffen School of Medicine at UCLA

37-year-old white male with severe upper GI bleed (UGIB) presented to the ER with melena and hematemesis. He had bright red blood (BRB) through a nasogastric (NG) tube & hypotension. He had a history of chronic alcoholism and a blood alcohol level of 0.15. He was tremulous but still oriented in ER. His lab profile showed hemoglobin (Hgb) of 6, international normalized ratio (INR) of 1.2, platelet 97,000, liver function tests (LFT) were normal except the transaminases were in the 80's.

The patient was resuscitated with IV fluids. He was sedated and because of deteriorating mental status was intubated, & transferred to the ICU. Octreotide & proton pump inhibitor (PPI) boluses plus infusions were given. The NG tube aspirate became coffee grounds. He then had an urgent EGD in ICU.

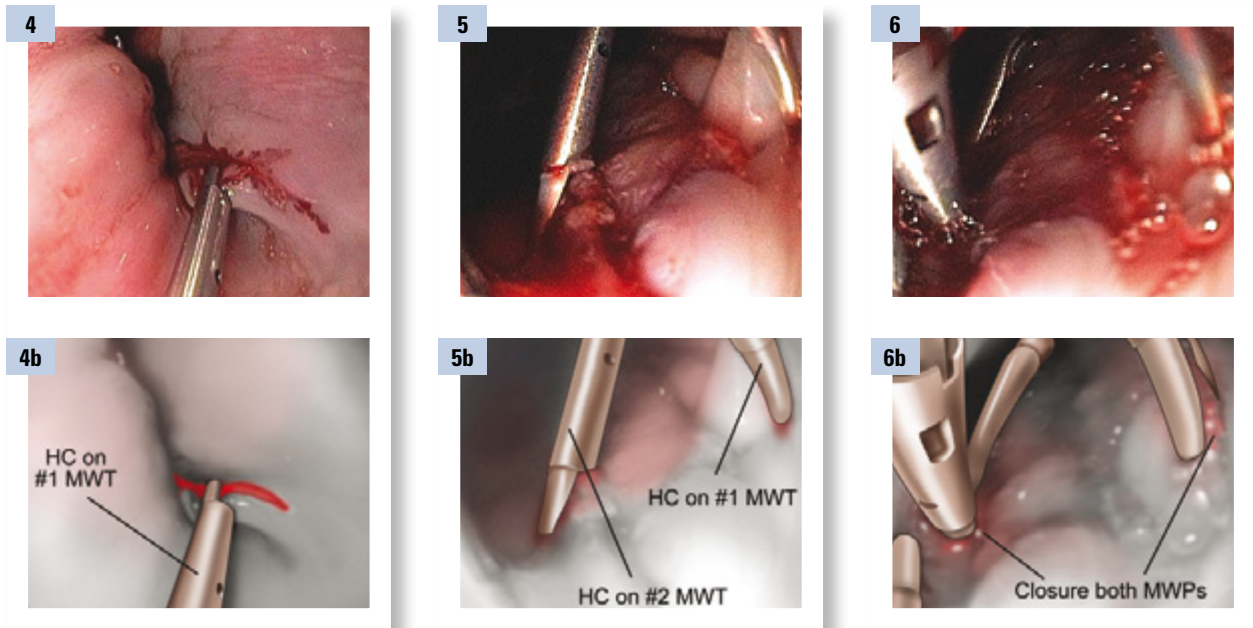


The initial differential diagnosis included esophageal or gastric varices, ulcers, or Mallory Weiss tears. The severity of the UGI bleeding and acuity was not characteristic of portal hypertensive gastropathy in this patient with mild coagulopathies.

On emergency endoscopy, there were no esophageal varices (Figure 1), but two bleeding Mallory Weiss (MW) tears were present. One was longer at the gastroesophageal junction (GEJ), and in the 3 o'clock position. The other was shorter, oozing, and was in the 7 o'clock position. A moderate sized hiatal hernia (HH) was present.

The oozing bleeding (Figure 2) cleared with target irrigation, but recurred. Therefore, for the longer MW tear, pre-injection was performed with low dose epinephrine (1:20,000) along the edge of this tear (Figure 3).





For the longer tear, 3 hemoclips (Resolution Clips) were placed from the distal portion of the MW tear to the proximal portion to close it (Figures 4-5). This controlled the bleeding. The shorter second MW tear was closed with 2 hemoclips (HC), which controlled the bleeding (Figure 6).

Follow-up

The patient was placed on anti-emetics and PPI's twice a day IV. As soon as he was extubated, he received a soft diet and oral PPI twice a day. He had no further bleeding and did not have a second endoscopy.

Q&A with Dr. Jensen

Why would you treat this stigmata?

A: Bleeding Mallory Weiss Tears (MWT) (2 in this case) were associated with portal hypertension (but no varices), severe bleeding, and thrombocytopenia. Combination epinephrine injection (to reduce bleeding) & hemoclips (HC) were used to treat both MWT.

Why inject first?

A: To reduce active bleeding (to see better) and to reduce any bleeding that can be induced from hemoclip (HC) contact to the MWT's.

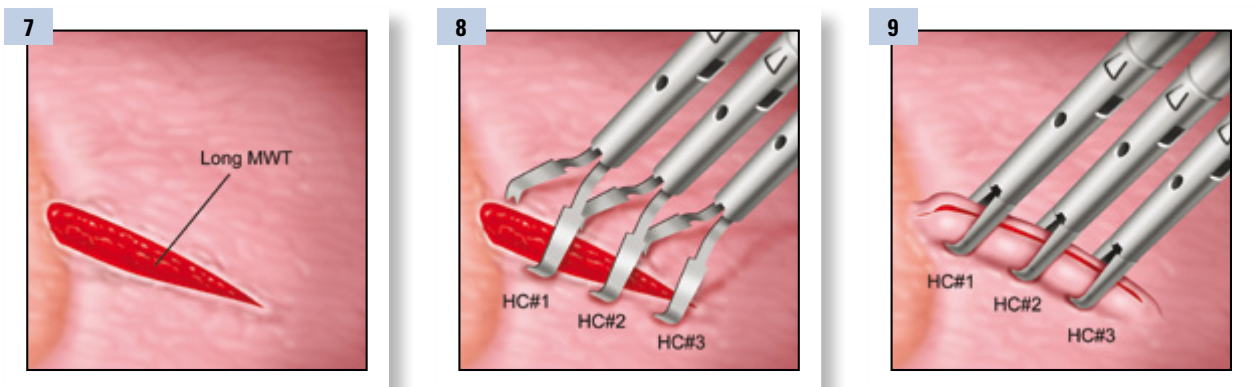
If there is good visualization of the lesion and only oozing bleeding, then epinephrine pre-injection is usually unnecessary.

Is there any medical therapy necessary?

A: Anti-emetics may reduce further vomiting and PPIs may accelerate healing of the MWT. An NG tube should be avoided. Soft diet should be considered for at least 72 hours. If the patient is anemic he can be discharged on oral iron.

How do you clip, and how do you know when you are done?

A: In the case of a long Mallory Weiss tear, hemoclip distal to proximal on MWT to zipper it closed as this will control bleeding and possibly facilitate healing (Figures 7-9).



Case 3: UGI Case – Epi Injection & Hemoclippping of 2 Bleeding Mallory Weiss Tears

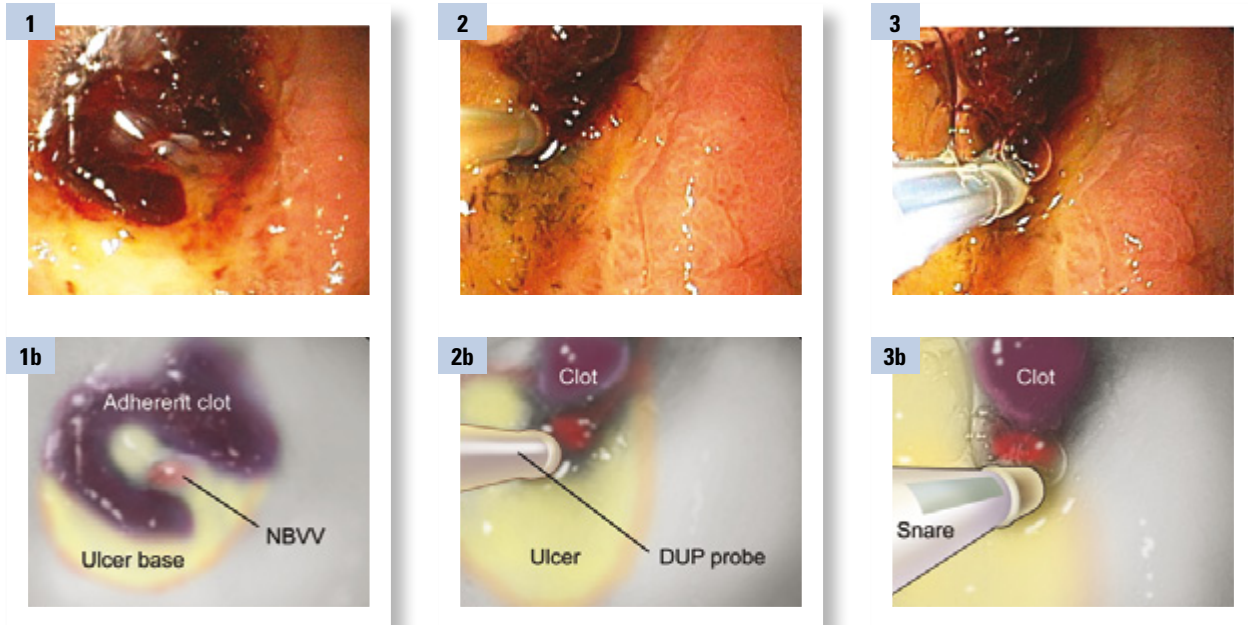


Case 4:

UGI Case – Doppler Probe, Injection & Hemoclippping of Giant Duodenal Ulcer (DU)

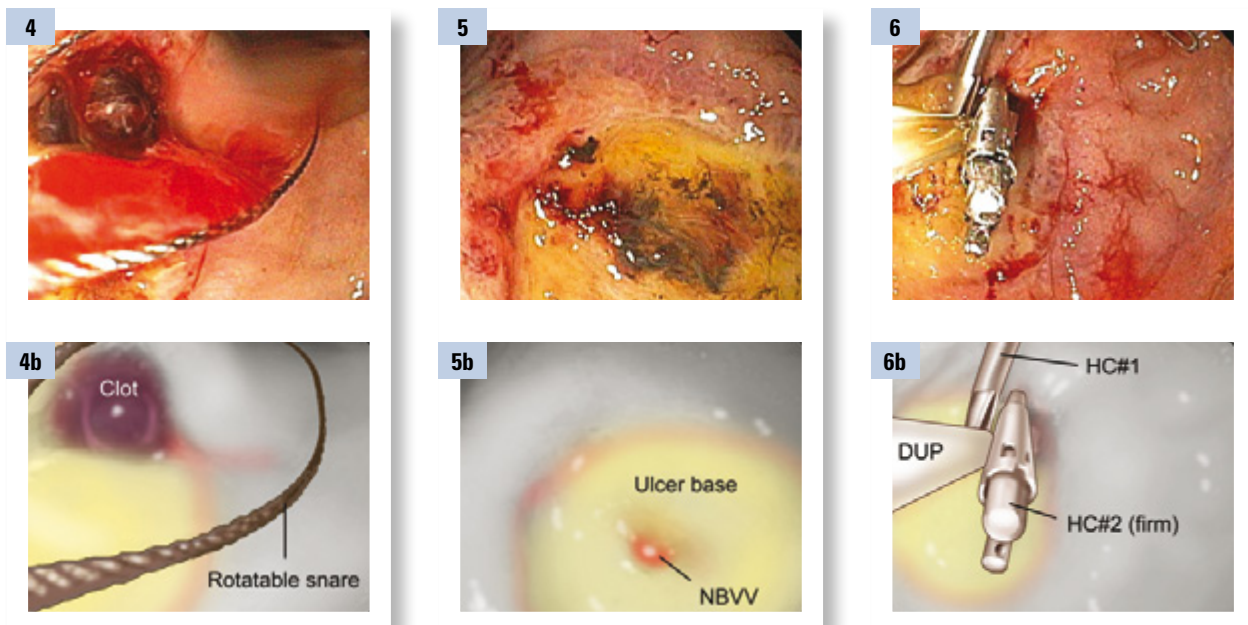
Case presented by: **Dennis M. Jensen, MD**, CURE DDRC, UCLA & VA Medical Centers, and David Geffen School of Medicine at UCLA

73-year-old Chinese male with severe in-patient start of melena. His hemoglobin (Hgb) dropped from 11.5 to 7.6 while on the hospital ward. Nasogastric (NG) tube aspirate was negative by the medical resident. He had chronic renal failure (on hemodialysis), a severe rash (thought to be possibly paraneoplastic), weight loss, & pneumonia.



For adherent clots on ulcer bases, it is necessary to shave these down with a snare to find out what stigma is underneath (Figure 1). By definition adherent clots cannot be washed off with target irrigation. Pre-injection with epinephrine markedly reduces induced bleeding. In this case doppler ultrasound probe (DUP) was positive (+) before Epi injection, indicating arterial blood flow under the clot (Figure 2).

One cannot target treatment of an ulcer with adherent clot without identifying the underlying stigma (usually a non-bleeding visible vessel (NBVV) as in this case). Pre-injection; snare guillotining to shave the clot down without pulling it off; and if necessary repeat Epi injection is safe (Figures 3-4). This patient had positive DUP before and a NBVV (Figure 5) after clot removal.



This patient had a DUP + (Figure 2) before clot removal indicating arterial blood flow. After clot removal by the cold guillotining technique (using a rotatable snare), a NBVV was found (Figure 5) and the DUP for underlying arterial blood flow was still positive. Therefore, 2 hemoclips (Resolution Clips) were used across the NBVV. This obliterated the underlying blood flow (Figure 6). Biopsies of the antrum and mid-body greater curvature were done for H.p.



This high risk patient was placed on proton pump inhibitors (PPI) IV (80 mg bolus and 8 mg/hr infusion) x 72 hours and then orally with PPI twice a day. He was treated with triple therapy for H. pylori infection. Ulcer bleeding did not recur. No neoplasm was found and he has remained on PPI and off aspirin and NSAIDs.

Q&A with Dr. Jensen

How do you remove an adherent clot without severe bleeding?

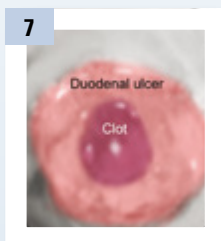
A: Use Pre-injection with epinephrine. Then with a rotatable snare we guillotine the clot in sections in order to shave it down without pulling it off the underlying vessel (Figures 7-10). During the process, if any bleeding occurs, repeat injection of Epi is safe and effective. After shaving down the pedicle of the clot to less than 3 or 4 mm, this pedicle or the underlying stigma which is usually a NBVV can be seen and treated with hemoclipping or other techniques (Figure 11). Blind clipping or coagulation of moderate or large sized clots does not reach the underlying vessel or seal it, so it is often unsuccessful. We have found this combination of endoscopic therapy along with medical therapy to be very effective. It reduces the rebleeding rate down to less than 5% as compared to over 30% with other endo techniques (Jensen adherent clot Gastro article 2002 volume 123:407).

Why, where and how do you clip?

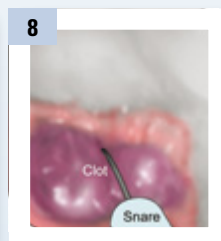
A: Rebleed rates of NBVV with underlying arterial blood flow are high. Combination therapies (such as Epi & hemoclips (HC) or multipolar electrocoagulation (MPEC)) reduce rebleed rates.

How do you know when you are done?

- A:** 1.) Visual: Firm grasp of NBVV with hemoclips (HC) (or flat & good coagulation with MPEC)
2.) DUP: Recheck & blood flow absent (vs. positive DUP before)



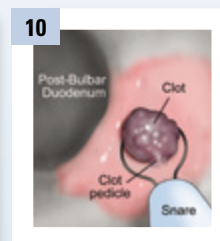7
Adherent clot-resistant to target irrigation



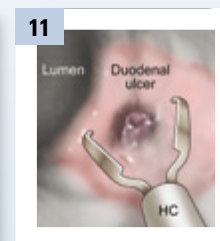
8
Guillotining top half of adherent clot



9
Delivery of clot tip into post-bulbar duodenum



10
Guillotining last half of adherent clot (Leaving a 3 - 4 mm pedicle)



11
Hemoclipping clot pedicle

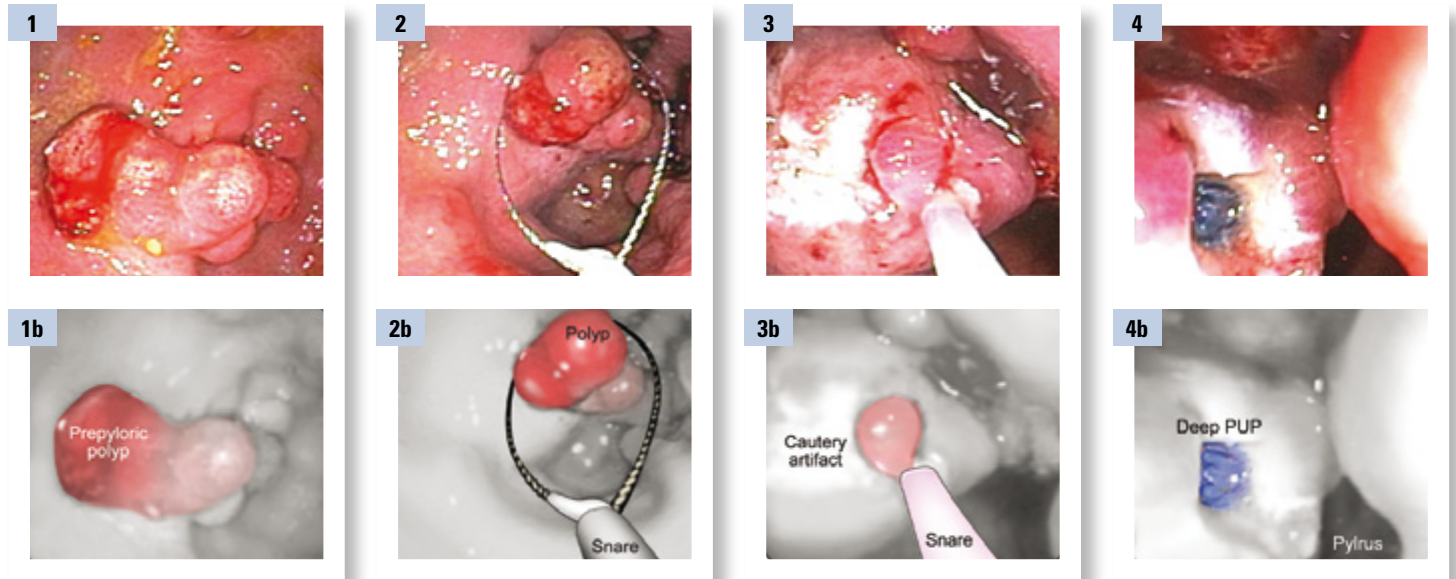


Case 5:

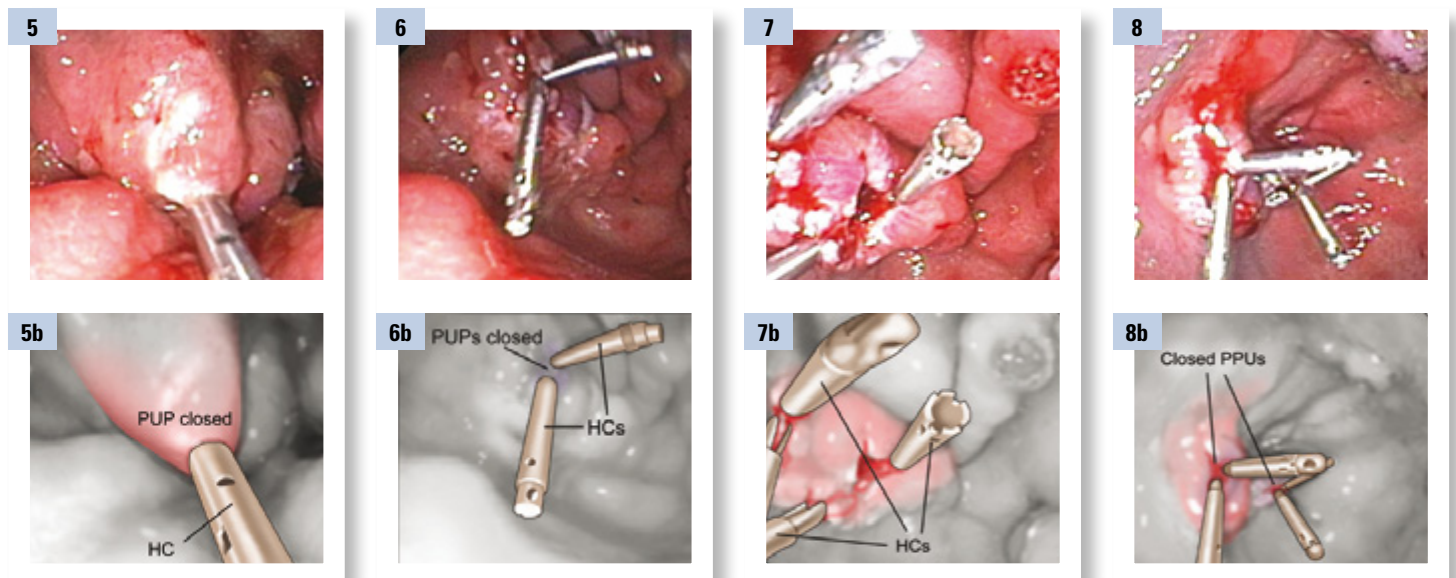
UGI Case – Hemoclipping of Polypectomy Sites

Case presented by: **Dennis M. Jensen, MD**, CURE DDRC, UCLA & VA Medical Centers, and David Geffen School of Medicine at UCLA

52-year-old white male with history more than 10 years ago of both liver & renal transplants. Both organs are failing. He is awaiting retransplant of both. He is on hemodialysis and lives in a neighboring state. While hospitalized for reevaluation he developed hematemesis and melena. His hemoglobin (Hgb) was 11, platelets 27,000, INR 1.6 and creatinine is 5.0. Because of the concern of malignancy while on long term immunosuppressants, a CT scan was done. It revealed an antral polyp & thickened antral folds which may represent lymphoma. He also has diabetes mellitus, weight loss, anemia, liver & renal failure. He had an elective endoscopy.



Multiple, multilobulated pre-pyloric sessile polyps were found. These appeared benign. These were friable and oozed with water irrigation or contact (Figures 1-2). A rotatable snare was utilized for piecemeal polypectomy after pre-injection (to raise the polyps off the submucosa with a saline, methylene blue mixture – (Figures 3-4)). The blue submucosa is evident after such treatment (Figure 4).



Hemoclips (Resolution Clips) were utilized to zipper the edges together (Figures 5-8). This required multiple hemoclips (HC) on each post-polypectomy induced ulcer (PPIU) to close them. The histopathology was benign (hyperplastic polyps without dysplasia or vascular ectasia). This patient received oral proton pump inhibitors (PPI's) for 48 hours before the EGD and polypectomies. He continued on PPI's twice a day for 5 weeks and did not have rebleeding during 60 days of GI follow-up. This is particularly noteworthy given his severe intrinsic coagulopathies. He awaits both liver and kidney transplantations.



Q&A

with Dr. Jensen

Why is it important to clip post polypectomy?

A: This patient has severe intrinsic coagulopathies, (high INR & very low platelet count) not reversible and related to his end stage renal disease & liver failure. He has a very high risk of delayed bleeding after gastric polypectomies.

How do you know where to start and when you are done?

A: Start at edge of PPIU and zipper closed with clips. PPIU closure is the goal and control of bleeding, if there is any.

How do you measure success?

A: No further rebleeding during follow-up and if feasible, documentation of post-polypectomy induced ulcer (PPIU) healing.

How common are these cases?

A: For the stomach, polyps are less common in US populations than polyps in the colon. However, in aging populations or those with transplantation and organ failure, coagulopathies are very common and delayed bleeding is of concern.



Case 6:

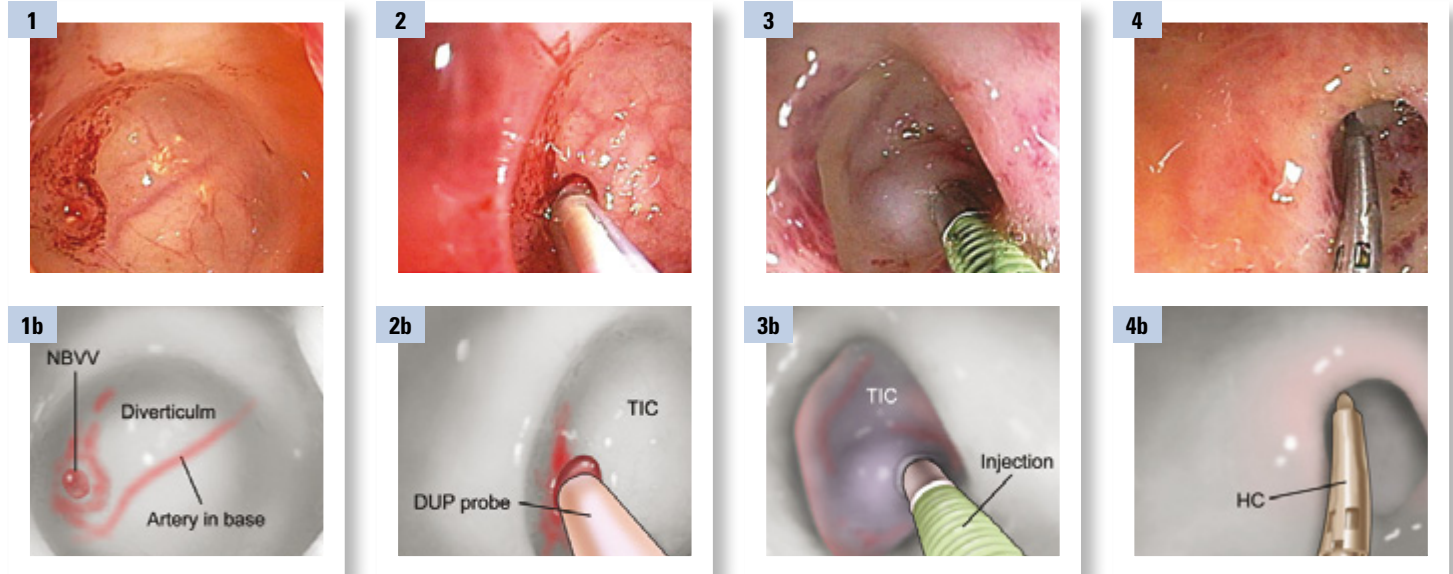
Colon Case – Sigmoid TIC with NBVV (pulsatile), Doppler Ultrasound Probe (DUP), Hemostasis (Epi Inj + clipping) & Tattoos

Case presented by: **Dennis M. Jensen, MD**, CURE DDRC, UCLA & VA Medical Centers, and David Geffen School of Medicine at UCLA

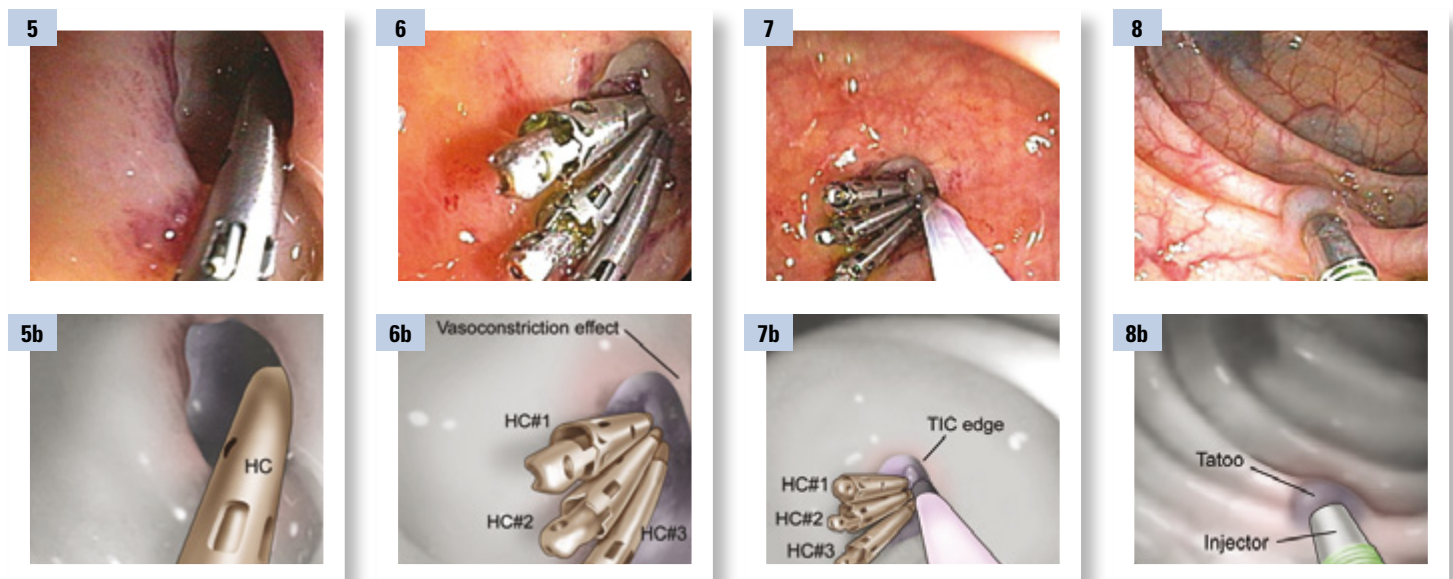
A 73-year-old African American female with polymyositis (on steroids), diabetes mellitus, obesity, & arthritis was admitted by her rheumatologist with painless hematochezia. Her hemoglobin (Hgb) fell from 13.5 to 10 with IV fluids & she had normal coagulation tests. There was no hypotension, melena or abdominal pain.

A nasogastric (NG) tube was placed & removed after bile was suctioned. A private GI saw the patient and ordered a colon prep of 4L of Golytely. Later that afternoon, he performed a colonoscopy which showed clots, blood & fluid throughout the colon and rectum, extensive diverticulosis without stigmata & large internal hemorrhoids.

That night, the hematochezia recurred and the Hgb dropped below 9.0. The GI hemostasis team was called to see the patient as a second opinion. The patient received 2 units of packed red blood cells (RBCs). She had an NG tube placed & received 7L of Golytely until the rectal effluent was clear of all clots and blood. An urgent colonoscopy was performed.



In about 50% of definitive diverticular hemorrhage cases (i.e. when major stigmata are found on urgent colonoscopy), the stigma is in the base of the diverticulum. In this case, a pulsative non-bleeding visible vessel (NBVV) was found (Figure 1) along the course of the artery in the base of the diverticulum. It was interrogated with a Doppler ultrasound probe (DUP) (Figure 2) and arterial blood flow just underneath the NBVV and adjacent to it (for 3-4 mm on each side along the artery) was detected. The colonoscope shaft and the diverticulum with the NBVV were then rotated 90 degrees counterclockwise so that the artery in the base of the diverticulum was in the vertical position (oriented 12 o'clock to 6 o'clock) to facilitate treatment with accessories that come out in the 5 o'clock position through the Olympus colonoscope suction channel. Then, two 1 cc epinephrine injections (1:20,000 in saline) were used around the NBVV in the base of the diverticulum and 3-4 mm along the artery on either side of the NBVV (Figure 3). These formed a bleb which raised up the base (Figures 2-3). Then the first hemoclip (Resolution™ Clip) was placed on the NBVV (Figure 4). The vasoconstrictive effects (purplish) are noted (Figures 3-4).



Subsequently two other hemoclips (HC) were placed in the base of the diverticulum, one on either side of the NBVV along the artery (Figures 5-6). Upon repeat DUP, no blood flow was detected (Figure 7). India ink (Spot) tattooing was used in three adjacent areas around the diverticulum to mark it, in case of rebleeding or the need for surgical resection (Figure 8).

The patient resumed a full liquid diet and her regular medications. She started her regular diet and activities within 24 hours and daily fiber. She has had no bleeding or complications and has been followed for three years, without recurrence of diverticular bleeding.



Q&A with Dr. Jensen

Why did you use two modalities?

A: Combination treatment with epinephrine injection (1:20,000) [x 2, injections of 1 cc each] & hemoclips (HC) was used. The epi injection prevents bleeding induced from the HC touching the NBVV, which was pulsatile & had underlying arterial flow documented.

Why was it important to clip?

A: Injection & HC [or multipolar electrocoagulation (MPEC)] are necessary for coaptive coagulation of the underlying artery & prevention of short & long term diverticular rebleeding. Epi alone does not cause definitive hemostasis of definitive diverticular hemorrhage (Figure 10).

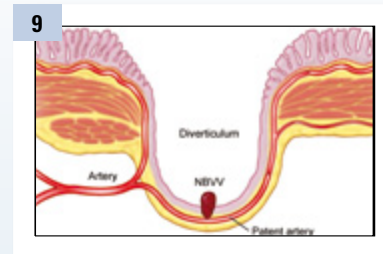
How did you determine where to place the first clip and the last clip?

A: The first HC was placed on the stigmata – the NBVV. Because of a positive (+) DUP (for blood flow) underneath and on either side of the NBVV at about 3-4 mm, 2 additional HC were placed (Figure 11).

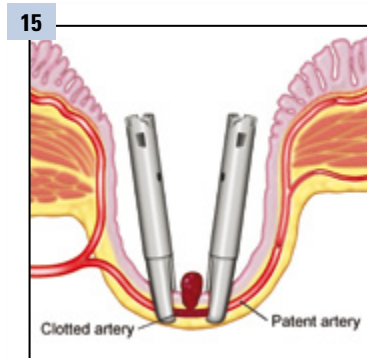
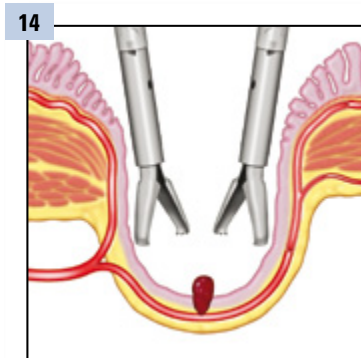
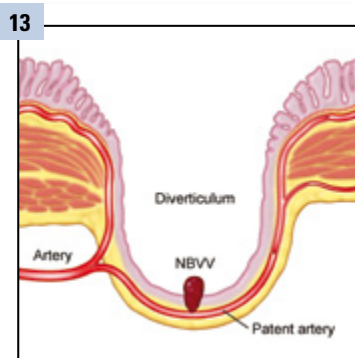
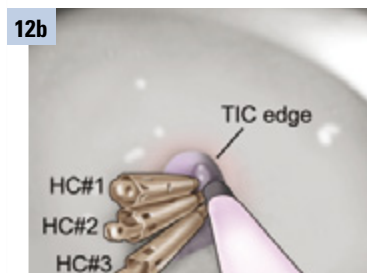
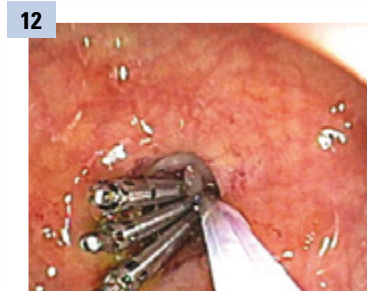
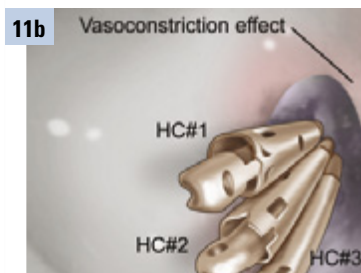
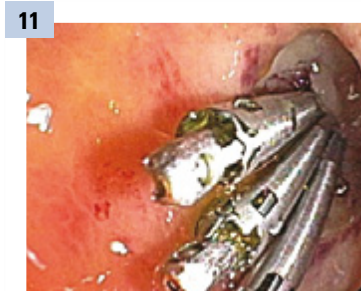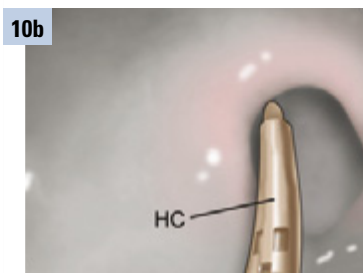
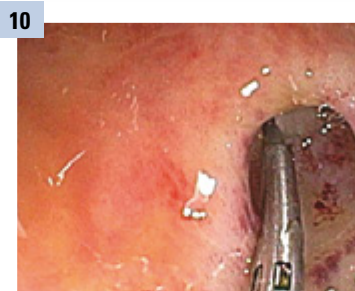Were the clips successful and how did you measure success?

- A:**
- 1.) NBVV clipped.
 - 2.) Artery in base of HC with + DUP (& superficial blood flow) clipped.
 - 3.) DUP – (negative) after treatment (Figure 12).
 - 4.) No rebleeding either within 30 days, or in this case for three years, without recurrence of diverticular bleeding.

Why do you prefer hemoclipping in the base of a diverticulum for a stigmata rather than using thermal coagulation which is faster?



A: This diagram of a colon diverticulum shows the penetrating vessels in the anatomy of the diverticulum including the base with a NBVV (Figures 9 & 13). The base has a thin mucosa, sub-mucosa with an artery and the serosa but no muscle there. The potential risks of thermal cautery are transmural injury, post-coagulation syndrome, and perforation often delayed. However, epi and clipping have not been associated with such injury. Hemoclipping is an important advance as approximately half of the stigmata of diverticular hemorrhage are found at the base of the diverticulum and can now be safely treated (Figures 14 & 15). The other half are found at the neck of the diverticulum and it is safe to use either thermal coagulation or hemoclipping for those.

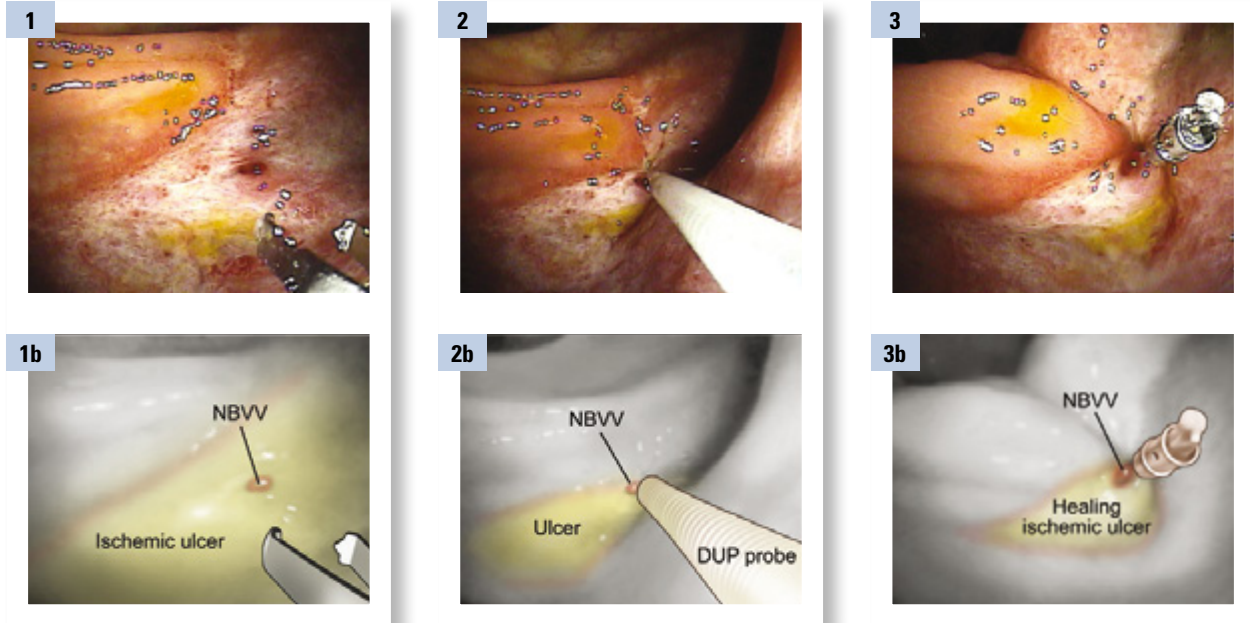


Case 7:

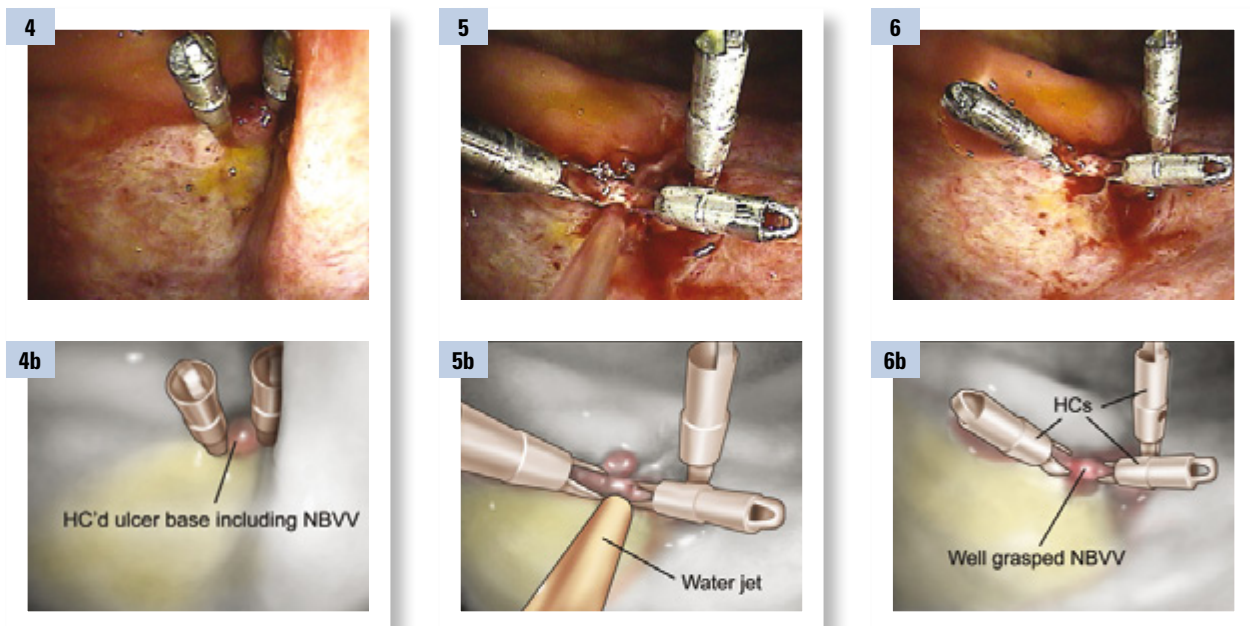
Colon Case – Injection-Hemoclip of Focal Ischemic Ulcer with Recurrent Inpatient Hematochezia

Case presented by: **Dennis M. Jensen, MD**, CURE DDRC, UCLA & VA Medical Centers, and David Geffen School of Medicine at UCLA

77-year-old African American male had severe inpatient hematochezia. He was hospitalized for 2 weeks with a urinary tract infection, chronic obstructive pulmonary disease (COPD), sepsis, diabetes mellitus, hypotension & myocardial infarction (non-Q wave MI) and dementia. Heparin (as deep vein thrombophlybitis phropholaxis) caused thrombocytopenia, down to 80,000. Therefore Lovenox® Drug was started. He developed bright red blood per rectum, hypotension, & the Hgb decreased from 10 to 6. After 4 units of red blood cells (RBCs), his hemoglobin (Hgb) was 9 and his platelets were 90,000 & INR 1.3. He was evaluated by the GI hemostasis team and was prepped for an urgent colonoscopy in the ICU.



He had a non-bleeding visible vessel (NBVV) on the large right colon ischemic ulcer that appeared to be healing (Figures 1 & 3). A Doppler Probe was used to irrigate the NBVV and there was arterial blood flow underneath (Figure 2).



Clips were placed across the NBVV until it was well and firmly grasped (Figures 4-6). You know when you are done upon visualization and no bleeding with target water jet irrigation (Figure 5). Firm grasp of NBVV and tissue adjacent in ulcer are other visual cues. If available, a Doppler probe can be used to recheck the underlying blood flow to ensure that it is negative, after hemoclips (HC).



The patient had no further bleeding but remained off anticoagulants. Focal bleeding ulcers with ischemic colitis are unusual but when found are a good indication for hemoclipping if that is thought to be the site of hemorrhage. The reason for this is that hemoclips (HC) do not cause significant tissue damage yet are able to grasp the underlying artery and reduce the chance of rebleeding.

Q&A with Dr. Jensen

Was the patient reversed prior to treatment? If so, why?

A: Heparin was stopped but the patient still had a platelet count of 90,000. There are no reversal agents for Lovenox® Drug or routine tests (like partial thromboplastin time (PTT)) to monitor Lovenox Drug effect. In this case no fresh frozen plasma was given nor platelets.

Why did you inject first?

A: Dilute epinephrine reduces blood flow & iatrogenic bleeding caused by touching the NBVV, spot, or artery during hemoclipping.

Once injected, why clip?

A: Epinephrine provides only temporary reduction in arterial blood flow in such patients and not permanent hemostasis. Hemoclipping or thermal coagulation can coapt the underlying artery and provide definitive hemostasis.

How do you clip?

A: Grasp tissue in the ulcer base and the stigmata. For chronic ulcers try to place as firmly & deep as possible across the stigmata. (see Figures 7-9 below)

Where do you start and why?

A: Pre-inject around stigmata about 0.5 – 1cc / injection x2-3. Place HC across stigmata to firmly grasp it or multipolar electrocoagulation (MPEC) directly & firmly on NBVV.

How do you know when you are done clipping and no further treatment is needed?

- A:** 1.) Stigmata and ulcer base are firmly grasped or well coagulated; there is no bleeding
2.) With Doppler probe (if available) underlying blood flow is halted.

How do you measure success?

A: No rebleeding clinically. No complications.

Is there any follow-up necessary following clipping a NBVV?

A: No, unless the patient rebleeds.

How do you recognize NBVV?

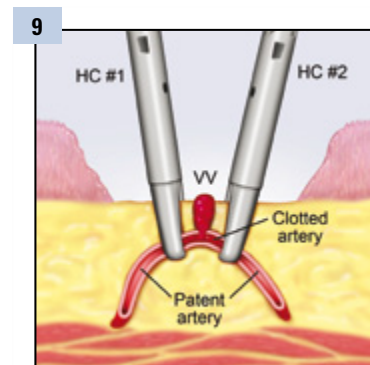
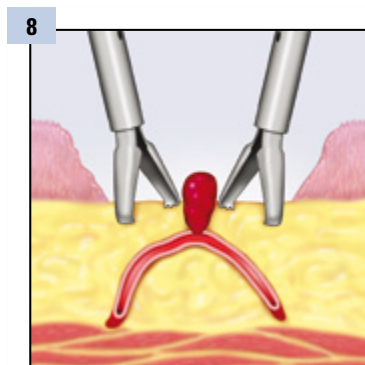
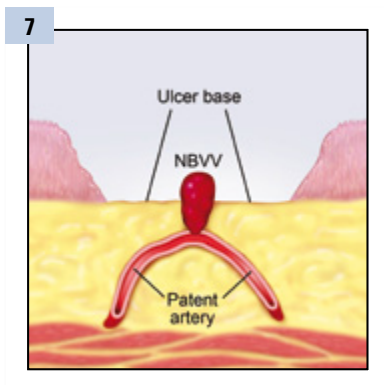
A: As a discrete small (< 5mm usually), raised, smooth protuberance in an ulcer crater. Distinct from a spot which is flat & from a clot that is amorphous & larger (> 6mm).

Why is it important to treat?

A: Rebleed rates of NBVV's in the colon for average risk patients are 40-50% & for high risk patients are 50-60%. Endoscopic treatments significantly reduce rebleeding.

Did anticoagulant medications aggravate the situation?

A: Anticoagulants may have contributed to inpatient bleeding and rebleeding (severe hematochezia) & worsened severity of bleeding.



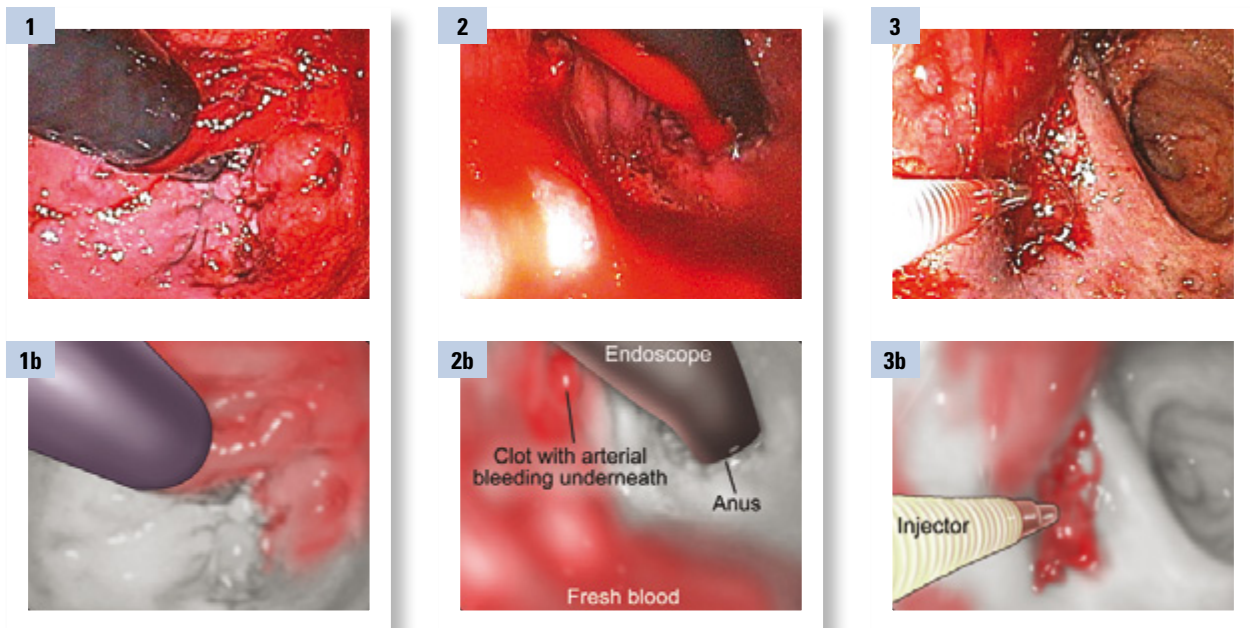
Case 8:

Colon Case – Spurting Rectal Ulcer: Hemostasis with Injection-Hemoclipping

Case presented by: **Dennis M. Jensen, MD**, CURE DDRC, UCLA & VA Medical Centers, and David Geffen School of Medicine at UCLA

52-year-old Hispanic man with end stage liver disease (ESLD) secondary to alcohol. He had ascites, encephalopathy, chronic renal failure on dialysis. He was evaluated for a liver transplant. He developed very severe inpatient hematochezia with shock. His hemoglobin (Hgb) decreased acutely from 11 to 5; His platelet count was 45,000, international normal ratio (INR) 2.5, PTT 60. He was transfused 12 units of red blood cells (RBC), 8 units of fresh frozen plasma (FFP), and 4 platelet pacs within 24 hrs. An emergency abdominal angiogram was performed but did not demonstrate a bleeding site.

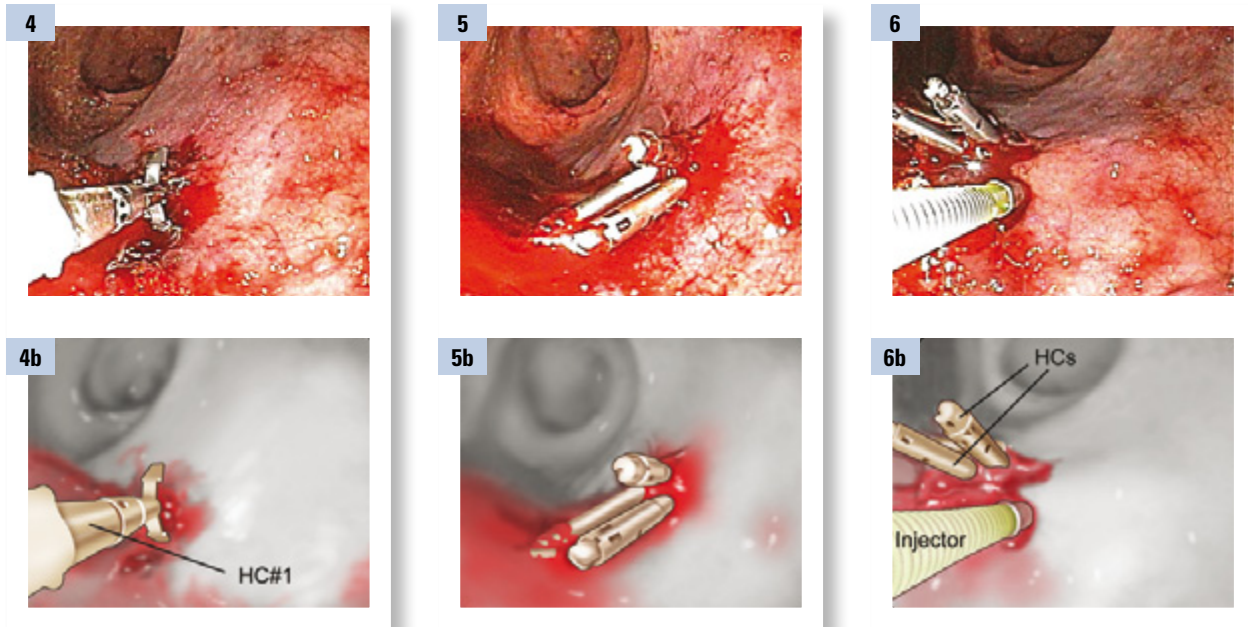
The patient was subsequently evaluated by the CURE/UCLA GI Hemostasis Team who recommended urgent colonoscopy after cleansing the colon with Golytely purge via a nasogastric (NG) tube. Continued transfusions of RBCs, platelets, and FFP were recommended, because of ongoing severe hematochezia and severe intrinsic coagulopathies. After metaclopramide (10 mg IV, repeated every 6 hours), the patient received a liter of purge every 30-45 minutes overnight. He still had some bright red bloods (BRB) in the morning in spite of 12 liters of Golytely over 8 hours. Nevertheless, an urgent colonoscopy at the bedside was performed.



On retroflexion examination in the rectum during urgent colonoscopy, active bleeding was found (Figure 1). The blood and clots extended all the way to the splenic flexure on urgent colonoscopy, but no other lesions (such as diverticulosis) were seen. Proximal to the splenic flexure, no lesions, polyps, or blood was seen.

Thereafter, efforts were focused on the rectum to identify a bleeding site. Suctioning, target irrigation, and examinations in the end-on and retroflexed positions were utilized to identify a clot on a solitary rectal ulcer with pulsatile arterial bleeding (Figure 2-3). This was injected with epinephrine (1:20,000 in saline) in 4 quadrants around adherent clot (Figure 3). This markedly reduced bleeding, so that with target irrigation, a focal ulcer with an adherent clot was localized.





The small adherent clot with oozing (that had been injected with epinephrine) was first hemoclipped (Resolution Clip) in the end-on position (Figure 4). Subsequently, 2 more hemoclips (HC) were placed (Figure 5-6). Because of continued oozing (related to severe intrinsic coagulopathies), 2 more epinephrine injections were made (Figure 6).

Follow-up

With further fresh frozen plasma (FFP) to reduce the INR below 2, there was no further hematochezia. He later received a liver transplant and had no further rectal bleeding.

Q&A with Dr. Jensen

Why did you clip?

A: In this patient with severe intrinsic coagulopathies, combination therapy (Injection + Hemoclipping) was necessary to control arterial bleeding from a rectal ulcer (RU). Hemoclipping was chosen instead of thermal coagulation because hemoclipping causes little or no tissue damage whereas thermal coagulation does and may increase the likelihood of RU rebleeding. RU closure was also possible with hemoclipping in this case & this may have accelerated healing and helped prevent rebleeding.

How did you clip? Why did you select the locations that you clipped?

A: See figure sequence 4 - 6 above.

We first placed a hemoclip on the site of active arterial bleeding, after epinephrine injection was used to slow the bleeding (Figures 4 & 5). Because of continued bleeding in this patient, hemoclips (HC) were also placed on either side of the bleeding site to try to stop active bleeding (Figure 5). To finally stop the bleeding further epi injections and tamponade with the epinephrine solution were required.

How did you know when you were successful?

A: First arterial bleeding was observed to stop after hemoclipping & more Epi injection underneath hemoclips (HC) for tamponade (Figure 6). Some oozing continued, but stopped with more fresh frozen plasma (FFP) & better correction of INR (to < 1.7) & transfusion of platelets (> 50,000). Another indication was that the patient did not rebleed.





DENNIS M. JENSEN, MD

Professor of Medicine
David Geffen School of Medicine at University of California, Los Angeles
Associate Director, Center for Ulcer Research and Education
Digestive Diseases Research Center (CURE DDRC)
Los Angeles, California

Dennis M. Jensen, M.D., earned his medical degree at the University of Washington Medical School in Seattle. He completed a medical internship and first-year medical residency at University of Oregon and Affiliated Hospitals. He served in the US Army Medical Corps as a Preventive Medicine Staff Officer. Then he completed a second-year medical residency at Wadsworth Veterans Administration (VA) Hospital in Los Angeles, and a fellowship in gastroenterology through a joint program of UCLA and Wadsworth VA Hospitals. He has been on the faculty at these institutions and a member of CURE DDRC since completion of his GI fellowship training.

Dr. Jensen is currently Professor of Medicine at the David Geffen School of Medicine at the University of California, Los Angeles (UCLA). He is also Associate Director of the Center for Ulcer Research and Education (CURE) Digestive Diseases Research Center and Key Investigator at CURE. In addition, he is a full-time staff physician in the Division of Digestive Diseases at the UCLA Center for the Health Sciences, where he is also Director of the Gastrointestinal Endoscopy Section. He is also a part-time staff physician in the GI Section of the VA Greater Los Angeles Healthcare Center. He directs the CURE Hemostasis Research Group which performs research, teaching, and patient care at UCLA and the West LA VA Hospitals.

Dr. Jensen's research includes multicenter, prospective and randomized controlled trials in endoscopic hemostasis and secondary prevention of gastrointestinal hemorrhage; GI outcomes and health services studies; and endoscopic technology assessment research. He has been the principal investigator (PI) or co-investigator on multiple studies jointly funded by the National Institutes of Health (NIH) and the National Institute of Diabetes and Digestive and Kidney Diseases (NIDDK). Also, he currently receives VA funding (Merit Review grant) and has received other research funding from the VA, Department of Defense, American Society for Gastrointestinal Endoscopy (ASGE), and industry. He has been a member of the VA Merit Review Board and the NIH Reviewers Reserve for special study sections, review of K awards, and site visits of proposals concerning gastrointestinal endoscopy, randomized controlled trials, GI technology, and clinical and outcomes research studies.

Dr. Jensen has published more than 215 peer-reviewed papers, case reports, chapters, books, and reviews. Dr. Jensen sits on several editorial boards and is a regular reviewer for such peer-reviewed journals as the New England Journal of Medicine, Annals of Internal Medicine, JAMA, Gastroenterology, American Journal of Gastroenterology, Gastrointestinal Endoscopy, and Endoscopy.

Dr. Jensen has successfully mentored many young clinical, outcomes, and endoscopy investigators for research and career development for over 30 years. Many of his trainees are full-time faculty or clinical faculty of academic medical centers. He is the PI and director of an NIH Training grant for gastroenterology and has funding of an NIH K24 grant for mentoring and clinical research. He has received both local and national awards as a distinguished lecturer, educator, and clinical researcher.



Resolution is a registered trademark of Boston Scientific Corporation or its affiliates.
All other trademarks are property of their respective owner.

The procedures and patient care expressed or depicted in these cases are those of the physician and do not necessarily reflect the opinions, policies or recommendations of Boston Scientific Corporation or any of its employees.

For further information and detailed instructions on the use of Boston Scientific Corporation's products, please refer to the Instructions for Use included with Boston Scientific's product packages.

All cited trademarks are the property of their respective owners. CAUTION: The law restricts these devices to sale by or on the order of a physician. Indications, contraindications, warnings and instructions for use can be found in the product labeling supplied with each device. Information for the use only in countries with applicable health authority product registrations.

**Boston
Scientific**
Advancing science for life™

www.bostonscientific-international.com

RCS Nanterre B420 668 420
© 2013 Boston Scientific Corporation
or its affiliates. All rights reserved.
ENDO-64506-AB June 2013

