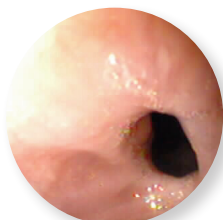


# Refractory Anastomotic Esophageal Stricture



**James S. Barthel, MD, FACP, FACG**  
Tampa, FL

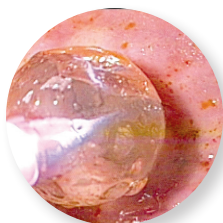
*"I think this has the potential to revolutionize the management of refractory anastomotic strictures of the esophagus following transhiatal esophagectomy."*



6 mm stricture

## Patient History and Assessment

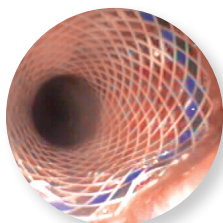
This is a 51-year-old man who underwent neo-adjuvant chemo radiation therapy followed by a transhiatal esophagectomy for treatment of adenocarcinoma arising from Barrett's Esophagus. Approximately three weeks after his surgery, he began to experience progressive dysphagia. About four to five weeks after the surgery, another endoscopy was performed and he was seen to have an anastomotic stricture at 24 cm from the incisors narrowed to about 6 mm of luminal diameter. The anastomotic stricture was dilated with balloons to about 14 mm. The patient subsequently returned for frequent serial dilations. In fact, he was being dilated about every eight days and underwent a total of seven serial dilations with the CRE™ Balloon Dilator before we elected to place a Polyflex Esophageal Stent.



CRE Balloon dilation

## Polyflex Esophageal Stent Placement

At the time of Polyflex Esophageal Stent placement, we dilated the patient again to 14 mm. A 16 mm body Polyflex Esophageal Stent was selected and placed across the stricture. The patient subsequently had relief of his dysphagia and had no further endoscopic interventions for 148 days.



Polyflex Esophageal Stent post placement

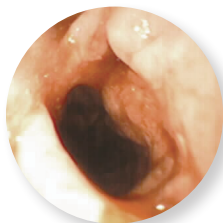## Follow-up Endoscopy and Removal (21 weeks post placement)

At the time we performed the endoscopy for removal, we found that the anastomotic stricture had completely stabilized and was wide open between 16 to 18 mm. The stent had fallen out of the stabilized stricture and had migrated into the stomach. The patient apparently had no symptoms from this and has subsequently been free of dysphagia and has done well.

In situations where I've had the opportunity to remove the stent from the actual stricture, I've found the rat tooth forceps easy to use. The patient has subsequently been free of dysphagia and has done well.

## Summary of Clinical Experience

We've had a total of five cases of refractory anastomotic strictures following transhiatal esophagectomy over the past 200 days or so and placed a total of seven Polyflex Esophageal Stents in those patients. Those patients as a group are doing very well. What we've seen is a tremendous difference in the number of interventions required to manage those patients with serial dilation versus placing an Polyflex Esophageal Stent. Specifically, in this five-patient series, the average length of time between dilations went from 6.8 days to 76 days.



Post stent removal - 12 wks  
16-18mm luminal patency

**Boston Scientific**  
Advancing science for life™

Boston Scientific Corporation  
One Boston Scientific Place  
Natick, MA 01760-1537  
[www.bostonscientific.com/endo-resources](http://www.bostonscientific.com/endo-resources)

**Ordering Information**  
**1.888.272.1001**

©2013 Boston Scientific Corporation or its affiliates. All rights reserved.

ENDO-181003-AA September 2013