



# DILATION ASSISTED STONE EXTRACTION (DASE)

---

LITERATURE REVIEW, PROCEDURAL TECHNIQUE AND CASE REPORT



*Presented by:*

Thomas E. Kowalski, MD

Oleh Haluszka, MD

Jeffrey L. Tokar, MD

# TABLE OF CONTENTS



LITERATURE REVIEW..... **1**



PROCEDURAL TECHNIQUE..... **2-3**



CASE REPORT..... **4**

## *Presented by:*

### **Thomas E. Kowalski, MD**

Associate Professor of Medicine  
Director of Gastrointestinal Endoscopy  
Thomas Jefferson University  
Philadelphia, Pennsylvania

### **Oleh Haluszka, MD**

Director of Gastrointestinal Endoscopy  
Fox Chase Cancer Center  
Philadelphia, Pennsylvania

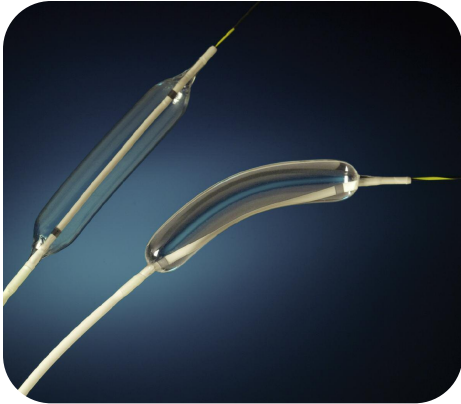
### **Jeffrey L. Tokar, MD**

Attending Gastroenterologist  
Fox Chase Cancer Center  
Philadelphia, Pennsylvania

## *Introduction*

Stone extraction is the most common purpose for performing ERCP. New data suggests that balloon dilation across the ampulla and distal bile duct following a sphincterotomy is an effective method for facilitating stone extraction. The objective of this document is to review recently published and presented data, and share a clinical experience utilizing this technique to remove biliary duct stones. Stone removal typically requires a sphincterotomy followed by extraction with a balloon or basket. Difficulties in stone extraction may be secondary to the stone(s) being too large to traverse the intrapancreatic portion of bile duct or the biliary sphincterotomy site. This can result in balloon rupture, increased procedure time, increased risk of complications such as pancreatitis, cholangitis, bleeding or perforation, frustration, and unsuccessful stone extraction.

DASE is a simple procedure requiring no additional ERCP skills or expertise. The success of DASE can potentially save the physician and patient from referral to a tertiary care center or surgery.



Since its introduction in 1974, endoscopic sphincterotomy (ES) has become the treatment of choice for biliary stone extraction.<sup>1-3</sup> Despite its long history of effectiveness and relative safety, sphincterotomy remains one of the most dangerous endoscopic procedures, with a complication rate of up to 10%.<sup>4</sup> In addition to the immediate risks of pancreatitis, bleeding, perforation, and even death, there remain the potential long term concerns for papillary stenosis and bacterial contamination of the biliary tree.<sup>5</sup> In an attempt to reduce these risks and to preserve the function of the Sphincter of Oddi, Staritz introduced the concept of papillary balloon dilatation.<sup>6,7</sup> This technique has a demonstrated stone clearance rate of 80-99%, and the technique has

become popular in parts of Europe and throughout Asia.<sup>8-10</sup> The technique has not been widely embraced in North America, largely due to a concern for pancreatitis. An international multicenter trial described a higher rate of pancreatitis in the group randomized to balloon dilatation as compared to the sphincterotomy group, and they reported two deaths as a result.<sup>11</sup> This has led most US endoscopists to avoid the technique altogether.

Although the majority of biliary stones can be extracted with a balloon or a basket following sphincterotomy, large stones as well as stones in the presence of several anatomic variants can make stone extraction difficult. These situations have resulted in a unique merging of biliary sphincterotomy and papillary balloon dilation. As originally described by Ersoz, the removal of large stones can be facilitated by sphincterotomy followed by dilatation of the ampulla and distal bile duct with a balloon.<sup>12</sup> It is hypothesized that sphincterotomy alters the forces of balloon dilatation, so that instead of being applied circumferentially, the greatest force will follow the pathway of least resistance or along the intraduodenal biliary segment in the direction of the sphincterotomy. This technique was described in 58 patients in whom endoscopic removal of bile duct stones by standard ES and balloon/basket extraction techniques had failed. Utilizing balloons ranging from 12 to 20 mm in diameter selected to match the size of the stone and the dilated segment of bile duct, they demonstrated a stone clearance of 83% after one session, with a success rate of 95% after two sessions without the need for mechanical lithotripsy. Their results were equally successful whether the patients had barrel shaped stones or stone extraction was prohibited by tapering of the distal bile duct. Complications occurred in 9 patients (15.5%) and consisted of cholangitis in 2 patients, mild pancreatitis in 2 patients, and bleeding in 5 patients.

Worldwide interest in this technique of dilation assisted stone extraction (DASE) was demonstrated at the 2007 Digestive Disease Week® in Washington, DC, and the United European Gastroenterology Week in Paris, France. We reviewed 9 abstracts that addressed the safety and efficacy of such a technique. Four of the abstracts were based on prospective studies, while 5 reported the results of retrospective data. Differences in techniques, methodologies and the limited clinical information restricted drawing generalizations and conclusions from these studies. However, when taken together the abstracts suggest the safety of this method, as only 8 patients out of a total of 523 (1.5%) were reported to experience pancreatitis.<sup>13-21</sup> If confirmed, that margin of safety, when coupled with the ability to extract stones without the need for lithotripsy, would make this a powerful tool for the biliary endoscopist.

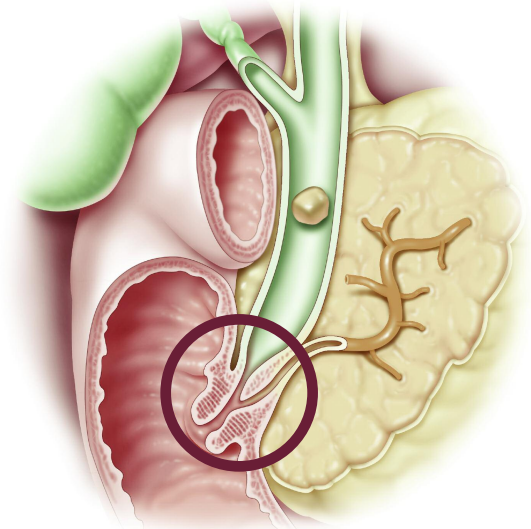


As currently practiced, Dilation Assisted Stone Extraction (DASE) can be utilized in situations in which stone size exceeds the diameter of the ampullary orifice or in which the intrapancreatic bile duct is too narrow to allow stone extraction without lithotripsy. (Figure 1)

**The steps of the technique involve:**

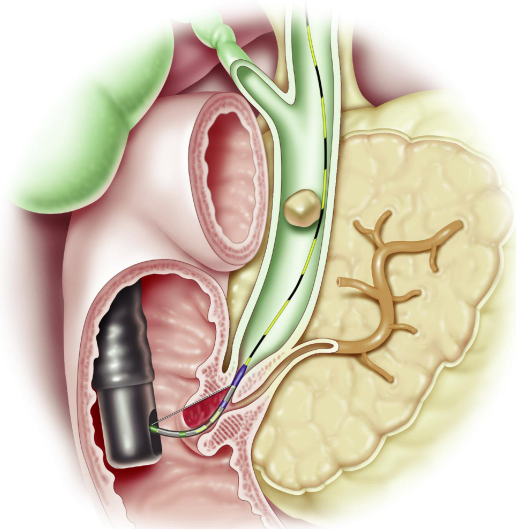
## STEP 1 Biliary Sphincterotomy

A guide wire is placed in the bile duct and a sphincterotomy is performed over the guide wire. The physician's standard sphincterotomy for stone extraction should be performed. When a physician is considering dilation assisted stone extraction, the extent of the sphincterotomy should not be limited as the safety of the technique likely depends on at least partially severing the sphincter muscle. The wire is advanced above the bifurcation to provide enough stiffness within the intrapancreatic and intraduodenal segments to facilitate the placement of the dilating balloon. (Figures 2 and 3)

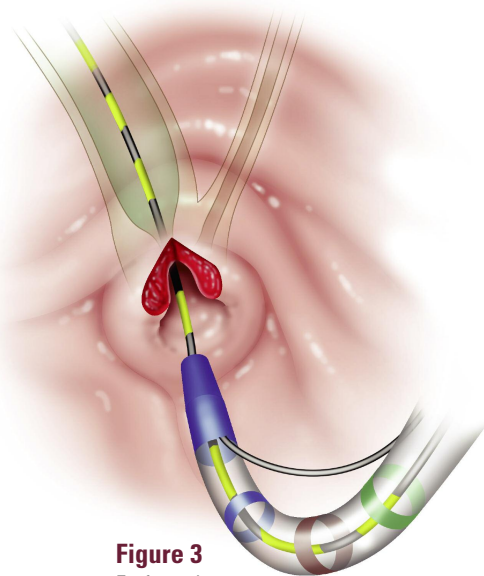


**Figure 1**

A dilated bile duct containing a large stone. There is narrowing of the distal bile duct just above the ampulla.



**Figure 2**



**Figure 3**

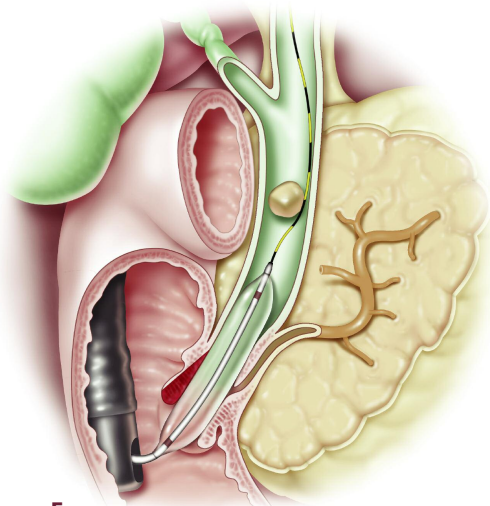
En face view

Post-sphincterotomy appearance with a nearly completely severed sphincter. The distal bile duct just proximal to the sphincter remains too narrow for the stone to pass.

## STEP 2

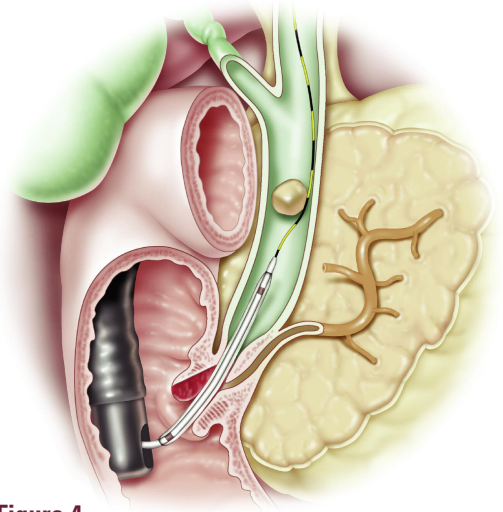
## Dilatation

The size of the balloon is determined by stone size and the diameter of the dilated bile duct. The balloon is positioned so its midpoint is at the biliary sphincter. The balloon should be inflated with a dilute contrast medium facilitating fluoroscopic monitoring. Gradual inflation is necessary under endoscopic and fluoroscopic monitoring to prevent the "watermelon seed" effect. It may be necessary to put either traction or inward pressure on the balloon catheter to maintain the balloon's position during inflation. Once the recommended balloon pressure is attained, inflation is maintained for 30-60 seconds. Rarely, the balloon waist is not obliterated and a second dilatation is required. If after inflation, the initial balloon diameter is felt to be too small, a second inflation using a larger diameter balloon can be performed. (Figures 4, 5 and 6)



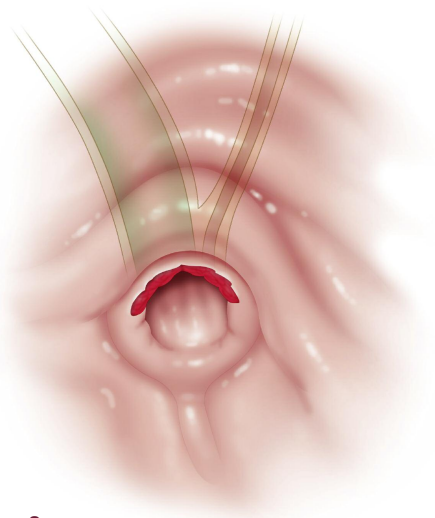
**Figure 5**

Inflated balloon across the remaining sphincter and the narrowed distal bile duct.



**Figure 4**

Dilation balloon prior to inflation positioned with the remaining sphincter at the midpoint between the proximal and distal markers.



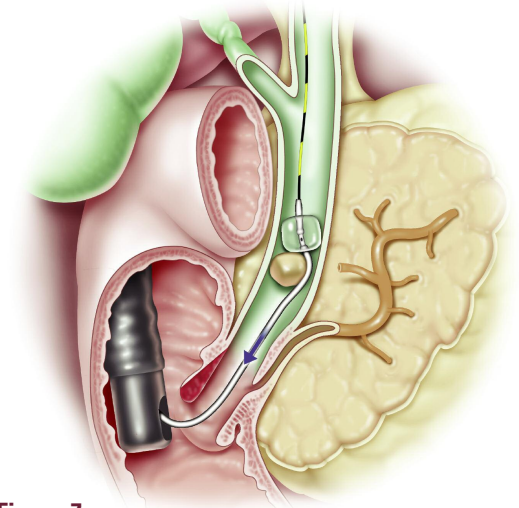
**Figure 6**

Post-dilation appearance - En face view

## STEP 3

## Stone Extraction

A standard retrieval balloon or basket may be used as necessary. (Figure 7)



**Figure 7**

An extraction balloon pulls down the stone. The residual sphincter has been obliterated and the distal narrowed bile duct has been dilated.



## Case Presented by:

**Oleh Haluszka, MD**

Director of Gastrointestinal Endoscopy

**Jeffrey L. Tokar, MD**

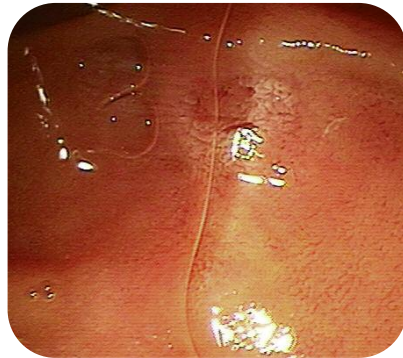Attending Gastroenterologist

Fox Chase Cancer Center  
Philadelphia, Pennsylvania

## Patient History and Assessment

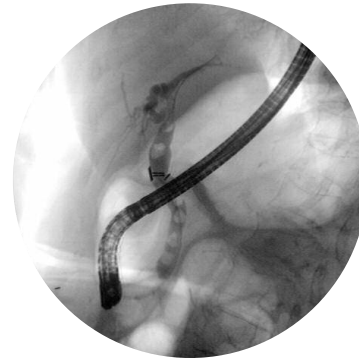
A 91-year-old female presented with recurrent nausea, vomiting, and epigastric abdominal pain. The patient had undergone open cholecystectomy approximately two decades earlier for symptomatic cholelithiasis. Past medical history was otherwise notable for hypertension, coronary artery disease with prior myocardial infarction, and a history of congestive heart failure. Laboratory studies, including liver function tests, were unrevealing.

A right upper quadrant ultrasound revealed intrahepatic and extrahepatic biliary dilation to the level of the ampulla, with multiple stones within the extrahepatic bile duct. The ampullary region and pancreatic duct were not well visualized. Subsequent magnetic resonance cholangiography confirmed the presence of multiple stones within the bile duct, as well as mild pancreatic duct dilation, and questionable fullness in the region of the major papilla (*Image 1 and 2*).



**Image 1**

At endoscopic retrograde cholangiopancreatography, a small, flat major papilla was identified.

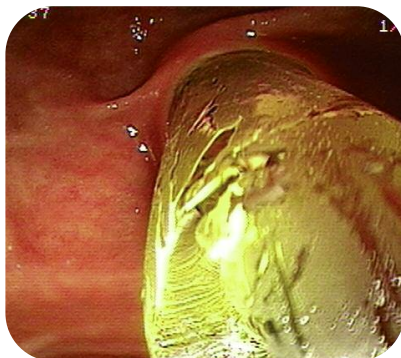

**Image 2**

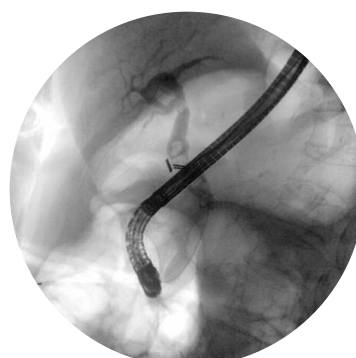Cholangiography confirmed the presence of multiple stones within the extrahepatic bile duct.

Dilation assisted stone extraction was chosen as the therapeutic intervention due to the small size of the native papilla, the presence of multiple and irregularly shaped stones, and the desire to achieve complete stone clearance in a single procedure to minimize anesthesia risks in the setting of multiple medical comorbidities.

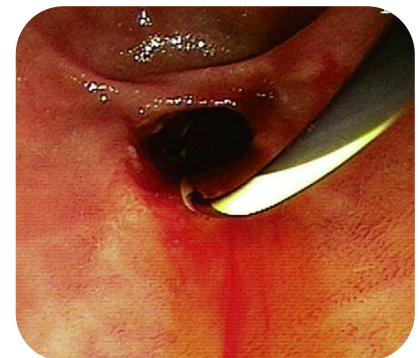In this case, a partial biliary sphincterotomy (4 mm) followed by a balloon sphincteroplasty (*Image 3 and 4*) was performed, resulting in a biliary orifice that facilitated complete stone extraction with a retrieval balloon (*Image 5*).



**Image 3**



**Image 4**



**Image 5**

## Summary/Conclusions

A growing body of evidence suggests that DASE represents a relatively simple and effective alternative method of stone extraction.<sup>22,23</sup> The procedure involves techniques already well known to biliary endoscopists. Dilating the distal bile duct and papillary orifice after endoscopic sphincterotomy facilitates the removal of stones that may otherwise require some form of lithotripsy for clearance. Experience suggests that the presence of the biliary sphincterotomy mitigates against the risk of pancreatitis, an extensively documented complication of standard biliary balloon sphincteroplasty alone. The primary indication is the case of large stones that cannot be removed by conventional balloon or basket sweep despite an adequate sphincterotomy.

Further prospective studies are necessary to validate and expand this indication. Future studies will need to address the role of DASE in special circumstances such as periampullary diverticulum, surgically altered anatomy (e.g. Billroth II), and in patients with coagulopathy. DASE is a valuable methodologic advance in the treatment of biliary stones and should be considered for cases of difficult extraction.

## References

1. Classen M, Demling L. Endoskopische sphinkterotomie der papilla Vateri und Stein extraction aus dem Duktus Choledochus. *Dtsch Med Wochenschr.* 1974;99:496-7.
2. Kawai K, Akasaka Y, Murakami K, Tada M, Koli Y. Endoscopic sphincterotomy of the ampulla of Vater. *Gastrointest Endosc.* 1974;20:148-51.
3. Sohma S, Tatekawa I, Okamoto Y, Matsuda T, Ono M, et al. Endoscopic papillotomy: a new approach for extraction of residual stones. *Gastrointest Endosc.* 1974;16:446-52.
4. Freeman ML, Nelson DB, Sherman S, Haber GB, Herman ME, Dorsher PJ, et al. Complications of endoscopic biliary sphincterotomy. *NEJM* 1996;335:909-18.
5. Bergmann JJ, Van der Mey S, Rauws EA, Tijssen JG, Gouma DJ, et al. Long-term follow-up after endoscopic sphincterotomy for bile duct stones in patients younger than 60 years of age. *Gastrointest Endosc.* 1996;44:643-9.
6. Staritz M, Ewe K, Meyer Zum Buschenfelde KH. Endoscopic papillary dilatation, a possible alternative to endoscopic papillotomy. *Lancet* 1982;1(8284):1306-7.
7. Staritz M, Ewe K, Meyer Zum Buschenfelde KH. Endoscopic papillary dilatation for the treatment of common bile duct stones and papillary stenosis. *Endoscopy.* 1983;15:197-8.
8. Mac Mathuna P, White P, Clarke E, Lennon J, Crowe J. Endoscopic sphincteroplasty: a novel and safe alternative to papillotomy in the management of bile duct stones. *Gut.* 1994;35:127-9.
9. Bergman J, Huibregtsek K. Endoscopic dilatation of the biliary sphincter for removal of bile duct stones: description of endoscopic techniques and a review of the literature. *Acta Endoscopica* 1997;27:405-15.
10. Tanaka S, Sawayama T, Yoshioka T. Endoscopic papillary balloon dilation and endoscopic sphincterotomy for bile duct stones: long term outcomes in a prospective randomized controlled trial. *Gastrointest Endosc.* 204;59:614-18.
11. DiSario JA, Freeman ML, Bjorkman DF, MacMathuna, P, Petersen BT. Endoscopic balloon dilation compared with sphincterotomy for extraction of bile duct stones: preliminary results. *Gastroenterology* 2004;127:1291-9.
12. Ersoz G, Tekesin O, Ozutemiz AO, Gunsar F. Biliary sphincterotomy plus dilatation with a large balloon for bile duct stones that are difficult to extract. *Gastrointest Endosc* 2003;57:156-159.
- 13.\* E. Valdivieso, H. Carlos, C. Castillo, S. Roque, C. Navarrete. Balloon Extended Sphincterotomy: Simple and safe technique to facilitate the management of a giant common bile duct stones.
- 14.\* M. Alnounou, J.L. Tokar, O.Haluszka. Combined partial endoscopic biliary sphincterotomy and endoscopic balloon sphincteroplasty in the management of difficult Bile duct Stones.
- 15.\* S.Cha, G. Choi, H.Go, A. Kim, H. Yang, Y. Lee, S.Jung. Endoscopic Large Balloon Sphincteroplasty for Removal of Large Bile Duct Stones in Patients with High Risk of Major Endoscopic Sphincterotomy related Complications.
- 16.\* D. Kang, J. Heo, S. Lee, G. Kim, T. Kim, J. Heo, G. Song, M. Cho. Endoscopic sphincterotomy plus large balloon dilation versus endoscopic sphincterotomy for removal of bile duct stones.
- 17.\* J. Eum, S. Bang, I. Jeong, S. Jung, J. Shin, N. Park, D. Kim, J. Lee, Y. Jung. Endoscopic Papillary Large Balloon Dilation compared to endoscopic sphincterotomy for removal of large Common Bile Duct Stones.
- 18.\* S. Attasaranya, Y. Cheon, L. McHenry, S. Sherman, S. Schmidt, J.L. Watkins, E.L. Fogel, H. Vittal, D.A. Howell, D. Wakelin, J.T. Cunningham, N. Ajmere, R. Ste. Marie, K. Bahattacharya, K. Gupta, M.L. Freeman, G.A. Lehman. Large-Diameter Papillary Balloon Dilation to Aid in Endoscopic Bile Duct Stone Removal: A Multicenter Series.
- 19.\* R. Nathwani, K. Banwait, L. Salese, D.E. Loren, T.E. Kowalski. Post-sphincterotomy transampullary balloon dilation is not associated with an increased incidence of post-ERCP pancreatitis.
- 20.\* A Minami. Small Sphincterotomy Combined with Papillary Dilation with Large Balloon Permits Retrieval of Large Stones Without Crushing – Forth report.
- 21.\* S. Park, K. Seo, G. Hong, D. Oh. Sphincterotomy Plus Large Balloon Papillary Dilatation for Large Bile Duct Stones.
22. Heo JH, Kang DH, Jung HJ, Kwon DS, An JK et al. Endoscopic sphincterotomy plus large balloon dilatation versus endoscopic sphincterotomy for removal of bile duct stones. *Gastrointest Endosc* 2007;66:720-6.
23. Maydeo A, Bhandari S, Balloon sphincteroplasty for removing difficult bile duct stones. *Endoscopy* 2007;39:958-61.

# Boston Scientific

*Delivering what's next.™*

Boston Scientific Corporation  
One Boston Scientific Place  
Natick, MA 01760-1537  
[www.bostonscientific.com/endoscopy](http://www.bostonscientific.com/endoscopy)

**Ordering Information**  
**1.800.225.3226**

© 2008 Boston Scientific Corporation  
or its affiliates. All rights reserved.

DVG2040 5M 1/08