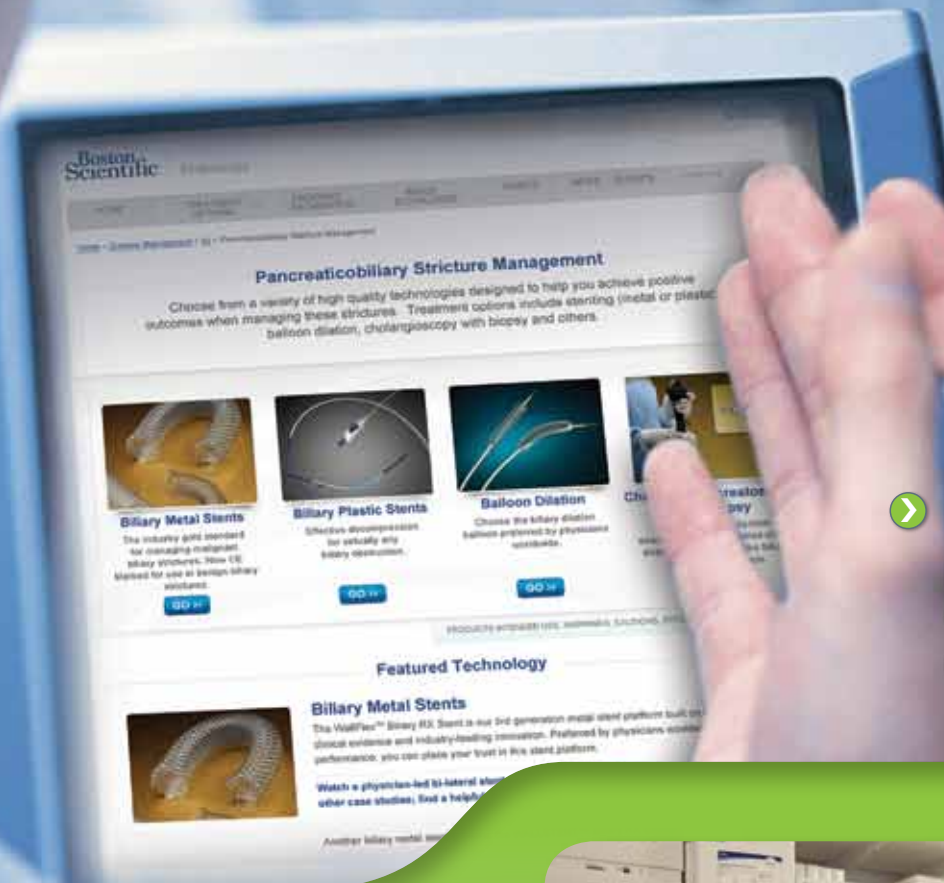

access

ENHANCING PATIENT OUTCOMES. DELIVERING TOTAL VALUE.™



➤ New website provides treatment options for a wide range of diseases

Beyond the Stock Room

A new inventory management approach leads Aintree University Hospital to more than cost savings.



A Message From Dave Pierce

Over the past five years, we have conducted clinical trials in 110 centers in 21 countries to provide evidence in support of best clinical practices, and proof of the safety and effectiveness of key technologies. We work regularly with gastroenterology and pulmonary specialty societies, and government agencies around the world to advocate for appropriate funding and reimbursement. And we continue to look for new ways to support the development of physicians and further the practice of endoscopy globally.



Dave Pierce speaks with employees at a national training meeting.

In June, the American Society for Gastrointestinal Endoscopy opened the doors of its new state-of-the-art training facility to provide integrated hands-on and didactic medical training in endoscopy and other medical specialties (p. 4). It is this type of vision and leadership that is critical to furthering the role of endoscopy in health care. Boston Scientific was a key financial supporter of this new facility, and proud to be a part of the work that is so important to the development of endoscopists.

Recently we announced our financial support for the American Gastroenterological Association (AGA) to help fund the AGA Research and Technology Fund Initiative. With support from industry, the AGA is able to ensure that researchers have the support they need to discover ways to better diagnose, treat and cure digestive diseases. Through the AGA's Center for GI Innovation and Technology, the AGA is working to foster innovation and the development of new technologies in gastroenterology, hepatology, nutrition and obesity.

In October we launched a new Treatment Options section of our Endoscopy Resources website (p. 18) to include both device and related clinical information. We've taken a disease management approach to organizing the site to make it easier for clinicians to navigate for information on stricture and stone management, stenting, hemostasis and more.

When it comes to education and development we support a variety of physician peer-to-peer events. Whether it's "pizza and endoscopy" sessions in Sao Palo, Brazil (p. 6) or hosting physicians from China for SpyGlass™ System training in the U.S. (p. 6), we are helping to create opportunities that meet a wide range of educational needs.

In this issue we have interesting cases (pp. 8-16) from physicians who offer insight and tips on procedural techniques on a variety of devices, including the new NaviPro™ Hydrophilic Guidewire and TWISTER® PLUS Rotatable Retrieval Device. In addition, there are cases on biliary and colonic stenting using our WallFlex™ Stents. WallFlex is our third-generation metal stent technology platform that is trusted by physicians around the world. It has and continues to play a key role in helping develop new treatment protocols and improve patient outcomes.

Also in this issue, learn about our work with Aintree University Hospital in Liverpool, England, and how we helped them develop a new way of managing inventory (p. 2). In addition to increasing operational efficiencies, Aintree clinicians can now spend less time ordering and tracking devices, and more time focused on patient care.


A handwritten signature in black ink, appearing to read "DAP".

Dave Pierce

Senior Vice President, Boston Scientific
President, Endoscopy Division

Inside This Issue

Articles

- | | | | |
|--|---|---|--|
|  | 2 Aintree University Hospital Turns to Boston Scientific to Help Improve Operational Efficiencies |  | 6 Physicians Create Informal Peer-to-Peer Education Opportunities with Help from Boston Scientific |
|  | 4 The ASGE's New Training Facility Lays the Groundwork for the Future |  | 7 An Interview with U.S. Physician Russell Yang, M.D. |
|  | 5 Boston Scientific Leverages Physician Expertise for Sales Training in the Asia-Pacific Region |  | 17 Closing the Gap in Colorectal and Pancreatic Cancers |
|  | 5 Boston Scientific Hosts 2013 Asia-Pacific Center of Excellence |  | 18 News and New Devices |
|  | 6 U.S. Physicians Share Expertise with Physicians Visiting From China |  | 18 New Section of Website Organizes Information by Treatment Options and Key Technologies |

Case Studies

- | | | | |
|--|---|---|----------------------------------|
|  | 8 NaviPro™ Hydrophilic Guidewire |  | 12-13 Expect™ Needle for EUS FNA |
|  | 8-9 WallFlex™ Stents |  | 14-16 Resolution™ Clip |
|  | 10-11 SpyGlass™ Direct Visualization System | | |

Online Global Resources

For the latest news and information from Boston Scientific Endoscopy, visit www.bostonscientific.com/endo-resources

INVENTORY SCANNED > STOCKED >

Aintree University Hospital Turns to Boston Scientific to Help Improve Operational Efficiencies

A new approach to managing inventory results in benefits for hospital, clinician and patient

In 2011, Aintree University Hospital in Liverpool, England, was faced with a challenge that many hospitals throughout the world are familiar with: the need to cut costs while retaining the highest level of safety and quality service for patients.



Aintree is a teaching hospital and tertiary center which provides specialty services to about 1.5 million residents in Merseyside, Cheshire, South Lancashire and North Wales, seeing approximately 500,000 patients annually. The hospital serves some of the most socially deprived communities with high levels of illness in the country. Aintree's vision is to provide world-class services for all patients with a common purpose of "getting it right for every patient, every time."

The hospital performs more than 18,000 endoscopy procedures annually. The Digestive Disease Clinical Business Unit orders almost all of its gastrointestinal, dilatation, biliary, hemostasis, polypectomy, biopsy and metal stent products from Boston Scientific. With the multitude of sizes and models available for each product within these categories, Aintree was stocking heavily to meet the specific needs of its clinicians and patients.

Victoria "Vikki" Jackson, deputy clinical business manager, managing the digestive diseases unit encompassing endoscopy,

gastroenterology and surgical services, was tasked with managing a cost-improvement process throughout the entire unit. She implemented several successful tactics but knew something with a greater impact had to be employed.

Jackson took a closer look at the inventory the hospital was carrying and found that the business unit's inventory and ordering systems were cumbersome to manage. The staff would move from one system to another to try to match items, download the information into spreadsheets and still had to cross reference entries throughout the entire process.

Jackson explained, "We were carrying a tremendous amount of inventory, in large part because staff would order product configurations that physicians wanted for specific patients. Then, for example, that patient would not arrive for a procedure and the product would end up sitting on the shelf, potentially going out of date. Also, the staff was using its monthly spend to order various sizes of products at each physician's request, making it difficult to keep track of which sizes of all the different products were in stock."

Jackson decided to turn to her Boston Scientific team to help develop a solution to better manage the hospital's inventory of Boston Scientific products.

1,500,000 residents
receive specialty services

500,000 patients
seen annually

18,000 Endoscopy
procedures annually

AND EXPIRATION DATES CHECKED

“Our relationship with Boston Scientific has developed into a trusted partnership throughout the years. We were able to communicate our requirements to them and they, in turn, helped us to meet our goals.”

— **Victoria Jackson**
Deputy Clinical Business Manager



“In the health care system, we have lots of challenges and pressures and still have to maintain quality. We have to make sure that we are using our resources to the best of our abilities. Boston Scientific sat down and worked through those challenges with us to find the right solution for us,” said Jackson.

EFFICIENCIES YIELD BENEFITS

The result was the implementation of a new, more efficient way to manage inventory. With this new in-stock solution in place, Aintree is realizing cost savings along with operational and clinical efficiencies. It’s also improving the patient experience.

“With the initial setup of our new inventory solution, we were able to see a consolidated view of our stock which included a six-to-eight-week window of product. We were able to use this current supply before having to purchase new items through the inventory solution once it went live. Because of this, there was a two-month up-front cost savings,” said Jackson.

Today, Aintree can determine what product it should have on hand to meet the needs of its physicians while also staying on budget. The solution enables the hospital to have the entire inventory scanned, stocked and checked for expiration dates. Under the new system, additional clinician time is freed up, allowing them to focus on giving patients the best care.

It’s now seamless for Aintree to have more options for products in stock and available to the physicians when they need them for particular cases. Under the previous system, if a patient procedure had to be cancelled and rescheduled because a product was not readily available, there was frustration and inefficiency for clinicians, administration and patients. Because the right stock is now available, Aintree no longer has these issues and can realize higher patient satisfaction.

“By working with Boston Scientific, we were able to find a more efficient way. Together we developed a solution that saves us time in ordering product, decreases the risk of purchased products expiring and enables us to have a more robust financial system to manage our consumables in a trackable and auditable way,” said Jackson.

A CROSS-FUNCTIONAL TEAM APPROACH

It took six to eight months from initial discussions between the hospital and Boston Scientific for the managed inventory solution to go live. Finance, procurement and IT were included in the process with representatives from both Aintree and Boston Scientific meeting regularly.

“Our relationship with Boston Scientific has developed into a trusted partnership throughout the years. We were able to communicate our requirements to them and they, in turn, helped us to meet our goals,” said Jackson.

The ASGE's New Training Facility

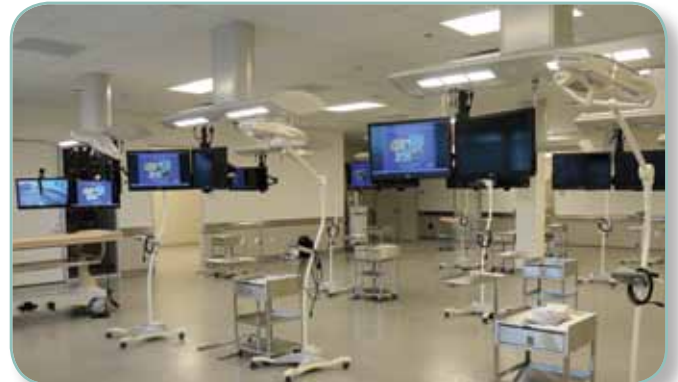Lays the Groundwork for the Future



In June, the American Society for Gastrointestinal Endoscopy (ASGE) opened its new Institute for Training and Technology (IT&T). Located in the Downers Grove suburb of Chicago, Illinois, the IT&T was designed as a state-of-the-art learning facility to support integrated hands-on and didactic medical training in endoscopy and other medical specialties.

“ASGE strives to advance patient care and digestive health through excellence and innovation in endoscopy. With its advanced technological capabilities and world-class bioskills lab, the new ASGE IT&T helps us further our mission,” said Dr. Kenneth Wang, president of the ASGE. “Industry partners such as Boston Scientific played a key role in making this facility a reality and we greatly appreciate their ongoing support.”

Prior to the new facility, training took place in a leased facility which the ASGE had outgrown, in terms of both space as well as technology, explained ASGE Chief Professional Education Officer Rebecca DeVivo. “It’s clear that the future of medical training is hands-on and our training facilities need to be state-of-the-art in order to meet physicians’ needs with new and emerging technologies,” said DeVivo.



The 40,000 square-foot facility offers a 100-plus-person auditorium, meeting rooms and a bioskills lab for hands-on training. The 2,800 square-foot Bioskills Lab supported by Boston Scientific has 16 fully equipped endoscopy stations, including two teaching stations with broadcast capabilities and 16 fully equipped endoscopic towers — all of which can be viewed from an adjacent observation deck.

Advanced audiovisual equipment with recording and archiving capabilities are available to support live as well as online and virtual learning. Connectivity is provided from room to room (auditorium, meeting rooms and bioskills lab). Internet and satellite can be used to broadcast worldwide in real time.

“ASGE strives to advance patient care and digestive health through excellence and innovation in endoscopy ... the new ASGE IT&T helps us further our mission. ”

— Dr. Kenneth Wang
President, ASGE

Boston Scientific Leverages Physician Expertise for Sales Training in the Asia-Pacific Region

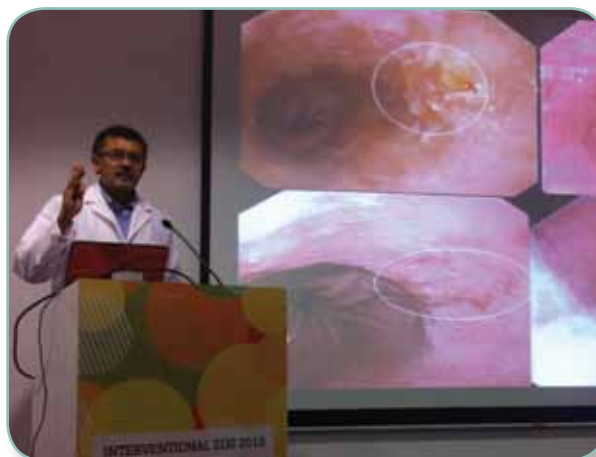Continuing education is key to providing best-in-class clinical case support

More than 20 Boston Scientific sales representatives from Korea, Taiwan, India and Australia participated in the Advanced Clinical Sales training event held June 2013 in Mumbai, India.

The training was held in collaboration with Amit Maydeo, M.D., chairman, Baldota Institute of Digestive Sciences, Global Hospital, Mumbai, India, and his faculty at the prestigious hospital. The week included lectures, live case observations, hands-on training and clinical literature workshops.

“ I have never seen a company like this before. I have never seen this type of training in my career. Truly fantastic.”

— **Dr. Amit Maydeo**
Chairman, Baldota Institute of Digestive Sciences, Global Hospital



Dr. Amit Maydeo presents a case at the Advanced Clinical Sales training event in Mumbai, India.

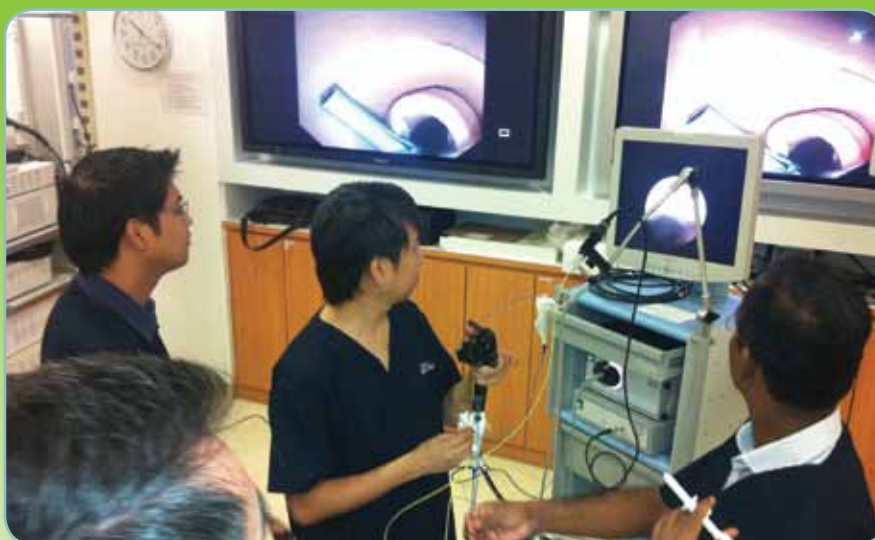
Boston Scientific Hosts 2013 Asia-Pacific Center of Excellence

Boston Scientific hosted more than 24 physicians and fellows at its third Center of Excellence Workshop

at the National University Hospital in Singapore, April 2013. Physicians and fellows from Korea, India, the Philippines, Vietnam, Bangladesh, Thailand and Taiwan participated in the event to gain hands-on experience with technology that would not normally be available in their regions.


Participants were able to perform mock procedures in a **state-of-the-art training facility** using gastrointestinal (GI) simulators for endoscopic retrograde cholangiopancreatography (ERCP), endoscopic ultrasound, and upper and lower GI procedures.

Participants also viewed **live cases in an endoscopy** suite and time allowed for in-depth discussion on the indications, applications and complications of diagnostic and therapeutic ERCP as well as pancreatico-biliary diseases and the impact of ERCP on these diseases. In addition, physician experts reviewed the endoscopic management of biliary strictures, difficult bile duct stones, malignant obstructive jaundice, pancreatic stones, pancreas divisum, and other pancreatic diseases.



Cannulating the common bile duct in a gastrointestinal simulator using the single operator SpyGlass™ Direct Visualization System.

U.S. Physicians Share Expertise with Physicians Visiting From China



Physicians from China visit St. Luke's hospital, Houston, Texas, during their visit to the U.S. and as part of their SpyGlass Direct Visualization System training.

Thirteen physicians from China made the most of their visit to the May 2013 Digestive Disease Week event held in Orlando, Florida, by participating in post-conference training hosted by Boston Scientific. The three-city, three-day tour included visits with Dr. Isaac Rajjman at The Digestive Associates of Houston, Texas; Dr. Michel Kahaleh at Weill Cornell Medical College, New York; and Dr. Raman Muthusamy at UCLA, California.

The host physicians shared their knowledge of diseases and endoscopic procedural techniques. Visiting physicians had the opportunity to observe difficult cholangioscopy cases using the SpyGlass™ Direct Visualization System in conjunction with electrohydraulic lithotripsy and holmium laser.

The SpyGlass™ Direct Visualization System is now available in China. The single-operator SpyGlass System enables direct visualization cholangioscopy for the detection and treatment of strictures and large stones in the pancreato-biliary system. See case studies in this issue pages 10-11.

Learn more about the SpyGlass System at www.bostonscientific.com/endo-resources under Treatment Options.



Physicians Create Informal Peer-to-Peer Education Opportunities with Help from Boston Scientific



With the demands of physicians' schedules, finding time to share knowledge and experiences is often limited to formal conferences and meetings.

With this in mind, Dr. Lucio Rossini from Santa Casa de São Paulo, and Dr. Eduardo Moura and Dr. Angelo Ferrari, both from the Universidade de São Paulo, came up with the idea for an event where such an exchange could take place in a more casual setting. With support from Boston Scientific these physicians were able to establish a regular meeting that has quickly grown in popularity and is now expanding its reach even further.

Known as "Pizza and Endoscopy," physicians gather about once a month to present and discuss cases and afterward have pizza for dinner. "Pizza and Endoscopy" has become a very important meeting in São Paulo because it is a place where, regardless of title, there is a candid discussion where everyone can learn something in a friendly and comfortable atmosphere," said Dr. Ferrari. "The meeting also gives physicians the opportunity to build relationships and expand their professional network."

Since its start in 2006, each session has been attended by an average of 70 physicians with 4-6 cases presented, including ample time for questions and discussion. Future meetings will be broadcast live via the Internet, expanding the meetings' reach to physicians beyond the Sao Paulo pizzeria. They will be able to view case presentations as well as participate in the discussion in real time via chat. The "Pizza and Endoscopy" sessions inspired others to hold similar events in Rio de Janeiro, Porto Alegre, Recife, Campinas and Minas Gerais.



AN INTERVIEW WITH U.S. PHYSICIAN

Russell Yang, M.D., on using the Radial Jaw 4 Jumbo Biopsy Forceps as an everyday forceps.

Q Does using Radial Jaw™ 4 Jumbo Biopsy Forceps help in terms of efficiencies?

Yes, I've found that you can do fewer passes through the biopsy channel when using Radial Jaw 4 Jumbo Biopsy Forceps. Jumbo forceps help with patient outcomes in a variety of ways. Primarily, I'm able to collect more tissue so I know I've obtained the greatest amount possible for the given situation and endoscopic procedure. In addition, the representative specimens I am able to obtain with jumbo forceps provide three times the volume and more than twice the surface area, giving me the appropriate sample for diagnosis. The most expensive procedure is the one you have to repeat.

Q What do you attribute to the increasingly larger cup size over the years?


It has been an interesting evolution. The first materials used for disposable forceps were made of plastic. However, the plastic forceps didn't work very well. Then low-cost stainless steel forceps were breaking and would frequently malfunction. Along the way, I found that different features play important roles that lead to overall functionality. For example, having a spike helps anchor the biopsy forceps into the tissue and allows the endoscopist to collect multiple samples. A more oval-shaped cup helps collect and scoop the tissue, which also makes it easier to extract tissue from the forceps. Size also makes a difference and we know that we need to maximize the size of the cup so it can fit through the largest channel of the majority of endoscopes. The benchmark has been set with Radial Jaw 4 Jumbo Forceps and now physicians expect to have forceps that fit easily into the endoscope without doing damage to the working channel. Such forceps can be more universally applied and in a greater variety of situations.

The benchmark has been set with Radial Jaw 4 Jumbo Forceps and now physicians expect to have forceps that fit easily into the endoscope without doing damage to the working channel.

Q Do you use jumbo forceps as your everyday forceps?

Radial Jaw 4 Jumbo Biopsy Forceps is my everyday go-to forceps. I have no complications using them, particularly on the days when I'm removing a lot of diminutive polyps. I like to have them available for use because they yield the best specimens and I can use them in many ways. Not only can they be used en face (directly at the lesion), they can also be used tangentially to remove small lesions and for tunnel biopsies of submucosal lesions. It really enhances the endoscopy experience by using instruments that you feel confident in and Radial Jaw 4 Jumbo Biopsy Forceps is one of those instruments.

Radial Jaw 4 Jumbo Biopsy Forceps is my everyday go-to forceps. I like to have them available for use because they yield the best specimens and I can use them in many ways.



New NaviPro Hydrophilic Guidewire for Multi-Stenting of Complex Malignant Hilar Strictures with Metal Stents



CASE PRESENTED BY:
VINCENZO PERRI, M.D.
IVO BOSKOSKI, M.D.
PROF. GUIDO COSTAMAGNA
 Digestive Endoscopy Unit
 Catholic University of Rome, ITALY

PATIENT HISTORY

This patient is an 87-year-old male with a complex malignant hilar stricture due to cholangiocarcinoma. Upon magnetic resonance cholangiopancreatography (MRCP), the stricture was found to be type III (Bismuth-Corlette). The patient previously underwent three endoscopic retrograde cholangiopancreatography procedures (ERCP) and the plastic stents were exchanged (**Figure 1**). Two months after the last ERCP, the patient presented with cholangitis and an urgent ERCP was performed.

PROCEDURE

The plastic stents were removed and there was an outflow of pus from the bile ducts. The complex hilar stricture type III was confirmed on cholangiography (**Figure 2**). After placing three NaviPro™ Hydrophilic Guidewires 0.035" (260cm, one standard and two stiff) (**Figure 3**), three uncovered WallFlex™ Stents, 10mm in diameter and 60mm in length were placed: two in two different right biliary ducts and one in the left biliary duct (**Figures 4, 5, 6**). Immediate contrast outflow was observed after placement of the stents (**Figure 7**).


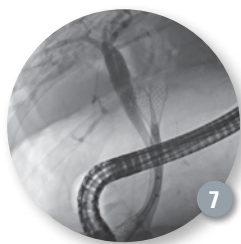
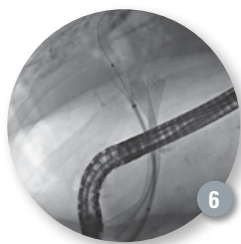
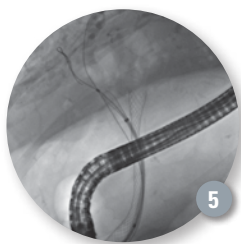
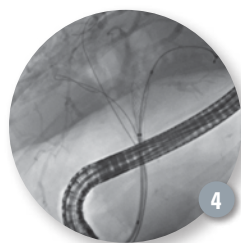
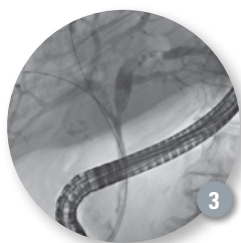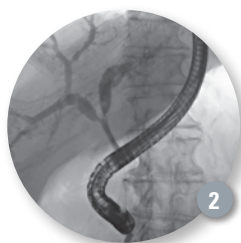
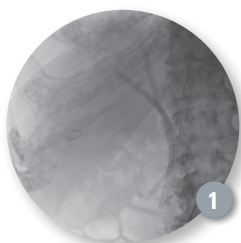
PATIENT OUTCOME AND CONCLUSION

The patient was discharged in good general condition the next day.

In order to avoid septic complications, it is very important to perform an MRCP mapping of the bile ducts and to understand the type of stricture. It is very important to drain all the opacified ducts.

Cannulation and overcoming tight biliary strictures can be done with the J-shaped NaviPro Guidewire. These new hydrophilic guidewires have a very good fluoroscopic visibility and are maneuverable (**Figure 3**). Three wires can be placed through the operative channel with insertion of the metal stents.

The WallFlex Stents with their intrinsic characteristics (very good and equilibrated radial and axial force) are well suited for use in complex malignant hilar strictures. These strictures are often very tight, so having good radial force is essential for complete expansion. The axial force of these stents is also important, especially for angulated ducts. The use of uncovered metal stents avoids closure of side biliary branches.



DISCLAIMER: Boston Scientific does not endorse the methodology of tri-lateral stenting as the sole method for treating malignant hilar strictures. As per ESGE guidelines, endoscopic drainage should be performed in high volume centers with experienced endoscopists and multidisciplinary teams (ref: Biliary stenting: Indications, choice of stents and results: European Society of Gastrointestinal Endoscopy (ESGE) clinical guidelines. Authors J.-M. Dumonceau, et al.).

NOTE: Use of the WallFlex Biliary RX Fully Covered Stent for the treatment of benign strictures or stenoses has not been cleared for use in the United States.

WARNING: The safety and effectiveness of the WallFlex Biliary Stent for use in the vascular system has not been established.

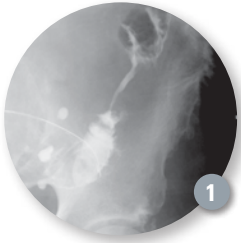
Therapeutic Endoscopic Management of Synchronous Colon Lesions



CASE PRESENTED BY:

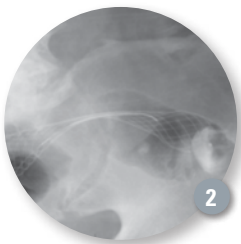
CHARLES LOEWE, M.D.

Center for Digestive Diseases
Sarasota, Florida, USA



INTRODUCTION

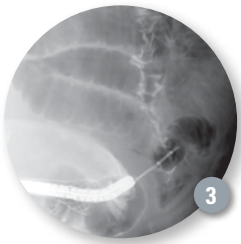
Synchronous lesions of the colon may present a challenge when trying to determine treatment algorithms for patients. Studies have reported the incidence of synchronous colon lesions between 4-8%^(1,2,3) and, if detected early, can often change the course of therapy that patients receive. The challenge for endoscopists is that synchronous lesions are difficult to identify pre-operatively because the distal lesions prevent examination of any proximal lesions. A computerized tomography colonography has been helpful to identify proximal lesions.



PATIENT HISTORY AND PROCEDURE

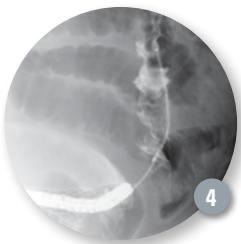
This is a case of an 86-year-old male who presented with a high-grade stricture in the lower left quadrant at the junction of the descending colon and sigmoid. The patient was scheduled for a WallFlex™ Colonic Stent placement to decompress the colon in preparation for surgery. A double-channel scope was utilized and advanced to the level of the stricture. A 450cm Jagwire™ Guidewire was advanced through the stricture and a ball-tip catheter was advanced over the guidewire. The catheter allowed for the injection of contrast to identify the appropriate length of the lesion.

Upon injection, a secondary lesion was noted and was consistent with a large bowel mucosal irregularity and the appearance of a malignant stricture (**Figure 1**).

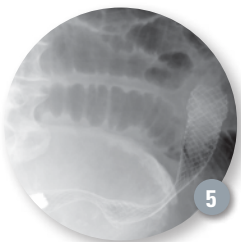


To allow optimal time for the WallFlex™ Colonic self-expanding metal stent (SEMS) to expand, a second stent procedure was scheduled three days later. In **Figure 2**, the compression of the stent from the primary colon lesion is observed; however, the impact of the SEMS on the lesion post-deployment, observed three days later, is evident. In order for endoscopists to safely consider pre-operative colonoscopy or secondary stenting of synchronous lesions, Vitale and colleagues waited an average of five days (range 4-8) and completed the colonoscopy under fluoroscopy⁽⁴⁾.

In **Figures 3 and 4**, during the second procedure, the colonoscope is fluoroscopically seen inside the first stent. Similar techniques were used to traverse the synchronous lesion utilizing a double-channel scope, a 450cm Jagwire™ Guidewire, contrast and a biliary extraction balloon.



In **Figure 5** it is observed that both lesions have been traversed by SEMS. It is noted that the waste in the proximal second stent is consistent with a stricture.



RECOMMENDATIONS

The management of acute colonic obstruction would benefit from a multidisciplinary approach to achieve the optimal outcome for the patient, whether it is for survival or palliation. Total large-bowel evaluation, preferably using colonoscopy under fluoroscopy, is essential in patients with cancer of the large bowel^(4, 5). **The use of colonic stents to relieve colonic obstructions may allow for a more complete colon examination and identification of synchronous lesions.**

References:

- 1) Vyas, J. J., Deshpande, R. K., Sharma, S. and Desai, P. B. (1983), Multiple primary cancers in Indian population: Metachronous and synchronous lesions. *J. Surg. Oncol.*, 23: 239-249. doi: 10.1002/jso.2930230406.
- 2) Sanna A. Mulder, Ries Kranse, Ronald A. Damhuis, Johannes H.W. de Wilt, Rob J.Th. Ouwendijk, Ernst J. Kuipers, Monique E. van Leerdam, Prevalence and prognosis of synchronous colorectal cancer: A Dutch population-based study, *Cancer Epidemiology*, Volume 35, Issue 5, October 2011, Pages 442-447, ISSN 1877-7821, 10.1016/j.canep.2010.12.007.
- 3) James M. Langevin, Santhar Nivatvongs, The true incidence of synchronous cancer of the large bowel: A prospective study, *The American Journal of Surgery*, Volume 147, Issue 3, March 1984, Pages 330-333, ISSN 0002-9610, 10.1016/0002-9610(84)90161-2. (<http://www.sciencedirect.com/science/article/pii/0002961084901612>)
- 4) Mario A. Vitale, Giuseppe Villotti, Lucia d'Alba, Stefano Frontespezi, Federico Iacopini, Giampaolo Iacopini, Preoperative colonoscopy after self-expandable metallic stent placement in patients with acute neoplastic colon obstruction, *Gastrointestinal Endoscopy*, Volume 63, Issue 6, May 2006, Pages 814-819, ISSN 0016-5107, 10.1016/j.gie.2005.12.032. <http://www.sciencedirect.com/science/article/pii/S0016510706000162>
- 5) Leandro Feo, David M Schaffzin Colonic stents: The modern treatment of colonic obstruction. *Advances in Therapy* (impact factor: 2.11). 01/2011; 28(2):73-86. DOI:10.1007/s12325-010-0094-6. Hahnemann University Hospital, Drexel University School of Medicine, Philadelphia, PA, USA.

Diagnosing Langerhans Cell Histiocytosis Using Direct Visualization for Tissue Sampling of Intraductal Lesions



CASE PRESENTED BY:

JAVIER PARRA, M.D.

Gastro Health
Miami, Florida, USA



INTRODUCTION

Langerhans cell histiocytosis is an uncommon disorder secondary to uncontrolled growth and activation of macrophages. These cells invade tissue and create lesions that affect the function of the determined organ, or produce pain and mass effect. This report is of a case of biliary Langerhans cell histiocytosis diagnosed by cholangioscopy, a first case of its kind.

PATIENT HISTORY

The patient is a 54-year-old male who presented to the emergency room with a multiple-week history of abdominal pain in the epigastrium to the right and left upper quadrants. This pain was episodic, sharp and intense, lasted for about 15 minutes at the time was relieved by itself. The patient had modified his diet, but there was an episode of pain that did not improve and, therefore, the patient came to the emergency room.

He had a history of diabetes insipidus and hypogonadism, and had undergone multiple MRIs of the brain that were reportedly normal. He was followed by an endocrinologist in Cuba and for the past 10 years in the U.S., where he was started on DDAVP.

He was initially afebrile, and his physical exam was only remarkable for mild pain on palpation of the epigastric area.

His initial laboratory tests showed normal sodium at 137, AST day one was 183, day two, 191; ALT day one was 581, day two, 375; alkaline phosphatase on day one was 604, day two, 479; total bilirubin on day one was 3 (direct 2.2), day two, 1.9 (direct 1.1).

A computed tomography of the abdomen showed geographic areas of attenuation with a mildly prominent bile duct in the left lobe and possible dilatation. There were also gallstones without cholecystitis visualized, and the patient refused magnetic resonance cholangiopancreatography (MRCP) due to his claustrophobia.

PROCEDURE

Since his LFTs were normalizing, it was decided he should undergo a laparoscopic cholecystectomy and intraoperative cholangiogram (IOC). The IOC visualized a stricture in the left hepatic duct and stones in the area of the bifurcation; therefore, the patient underwent an

endoscopic retrograde cholangiopancreatography where the stricture was documented, brushed and the stones evacuated after a sphincterotomy was performed. Brushings of the stricture were compatible with histiocytes, inflammatory cells and bile pigment.

To further clarify the nature of this stricture, the patient was then offered an MRCP, which he agreed to. This showed multiple areas of soft tissue densities along the aorta, and one stricture in the common bile duct as well as a stricture in the left main duct. There were enlarged lymph nodes throughout. Therefore, a cholangioscopy with biopsy was planned and an IgG4 was drawn.

The SpyGlass™ Direct Visualization System was used to perform cholangioscopy and demonstrated a mass in the lumen proximal to the cystic duct area, as well as involvement with an intraductal mass in the left main duct (**Figures 1, 2 and 3**). These areas were biopsied under direct visualization and video documentation was obtained.

Biopsies demonstrated fibrovascular tissue, eosinophils and Langerhans cells, which stained focally positive for Keratin AE-1-3 (**Figure 4**), and positive for S100 and CD1a (**Figure 5**). These findings are compatible with Langerhans cell histiocytosis.

This case report highlights the usefulness of obtaining direct visualization tissue sampling of intraductal lesions with the SpyGlass System. It demonstrates comparatively in the same patient a potentially missed diagnosis with brushing that was achieved by directly obtained samples.

DISCUSSION

This is the first reported case of cholangioscopy-assisted diagnosis of biliary Langerhans cell histiocytosis. The SpyGlass System aids in diagnosis by directly visualizing and sampling tissue in the pancreatico-biliary system, including intrabiliary mass lesions. Langerhans cells histiocytosis should be suspected in patients with diabetes insipidus and hypogonadism, or diffuse lymphadenopathy with biliary strictures accompanied by other systemic signs.

(References for this case on page 11)

Performing a 3D ERCP Using the SpyGlass System and Laser Lithotripsy for Hepatolithiasis




CASE PRESENTED BY:
FILIP NEUMANN, M.D.
Endoscopy Center
Kolin Hospital, CZECH REPUBLIC




PATIENT HISTORY

A 79-year-old male was admitted to the surgical department with fever, abdominal pain and obstructive icterus (jaundice). Laboratory tests showed elevated liver enzymes. A dilated common bile duct was visible on sonography. An abdominal computed tomography scan revealed the presence of cystic dilatation in hepatic segments SII and SIII - cholangiolar abscesses.



PROCEDURE

Standard endoscopic retrograde cholangiopancreatography (ERCP) evaluation showed middle dilatation of the left hepatic duct (**Figure 1**), followed by a 3D ERCP with multi-planar reconstruction using volume rendering technique in a diagnostic station (**Figure 2**). A rotated biliary tree showed two filling defects (**Figure 3**). After overfilling with contrast, described cholangiolar abscesses were visible. In the lateral view of the biliary tree, two defects consistent with hepatolithiasis were visible in the left hepatic duct. The SpyGlass™ Direct Visualization System was then inserted into the biliary duct, under optical control into the left hepatic duct. Here, concretions were visualized and laser lithotripsy was performed (10 W) under optical control (**Figures 4, 5 and 6**). Basket extraction was used to remove the stone fragments. The entire procedure was free of complications.

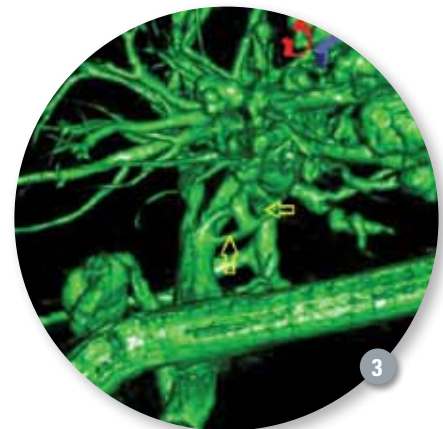
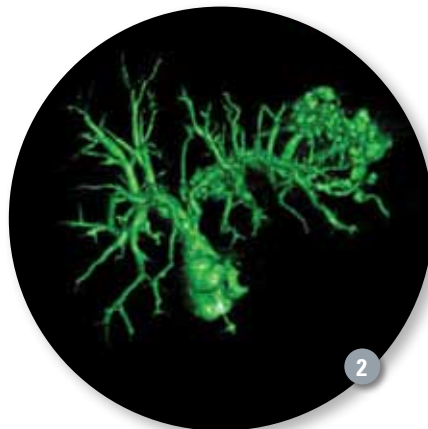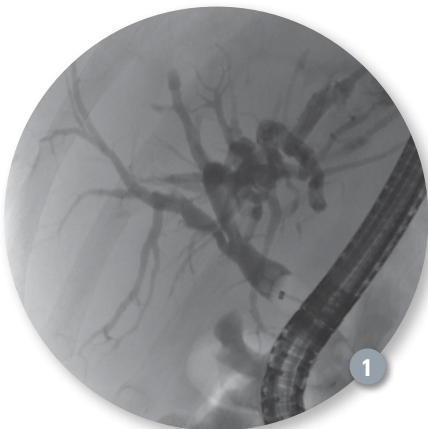


POST-PROCEDURE

The patient was released after antibiotic treatment. Now, two months after the procedure, the patient is without problems and his liver tests are normalized.

DISCUSSION

This case represents the use of advanced technologies such as 3D visualization of the biliary tree, cholangioscopy and laser lithotripsy for the diagnosis and treatment of cholangitis on hepatolithiasis etiology.



< (References for case presented by: Javier Parra, M.D. on page 10)

References for case presented by Dr. Parra:

Willman, Cheryl L.; Busque, Lambert; Griffith, Barbara B.; Favara, Blaise E.; McClain, Kenneth L.; Duncan, Marilyn H.; Gilliland, D. Gary (21 July 1994). "Langerhans' Cell Histiocytosis (Histiocytosis X) – A Clonal Proliferative Disease". *New England Journal of Medicine* 331 (3): 154–160. doi:10.1056/NEJM199407213310303. PMID 8008029.

Cotran, Ramzi S.; Kumar, Vinay; Abbas, Abul K.; Fausto, Nelson; Robbins, Stanley L. (2005). *Robbins and Cotran pathologic basis of disease*. St. Louis, Mo: Elsevier Saunders. pp. 701–. ISBN 0-8089-2302-1.

Sclerosing cholangitis revealing Langerhans cell histiocytosis in a 15-month-old child. Sabib M, Ettair S, Erreimi N, Mouane N. *Arch Pediatr*. 2011 Sep;18(9):974-8. doi: 10.1016/j.arcped.2011.06.018. Epub 2011 Aug 3. French. PMID: 21816590 [PubMed - indexed for MEDLINE]

Langerhans' cell histiocytosis of the liver in adults. Abdallah M, Généreau T, Donadieu J, Emile JF, Chazouillères O, Gaujoux-Viala C, Cabane J. *Clin Res Hepatol Gastroenterol*. 2011 Jun;35(6-7):475-81. doi: 10.1016/j.clinre.2011.03.012. Epub 2011 May 6. PMID: 21550330 [PubMed - indexed for MEDLINE]

Biliary manifestation of Erdheim-Chester disease mimicking Klatskin's carcinoma. Gundling F, Nerlich A, Heitland WU, Schepp W. *Am J Gastroenterol*. 2007 Feb;102(2):452-4. Epub 2006 Oct 13. PMID: 17037989 [PubMed - indexed for MEDLINE]

EUS FNA-Based Diagnosis of Abdominal Tuberculosis Masquerading as Pancreatic Cancer



CASE PRESENTED BY:

YOGESH BATRA¹, ROHIT GOYAL¹,
SUBHASHISH MAZUMDAR¹, SANJAY KHANNA¹,
DEEPTI MISHRA², GAURI BAHUGUNA², JC VIJ¹

1. Department of Gastroenterology

2. Department of Pathology

BLK Super Specialty Hospital, New Delhi, INDIA

INTRODUCTION

Endoscopic ultrasound (EUS)-guided fine-needle aspiration (FNA) is a recent advancement in the diagnostic armamentarium of the gastroenterologist. Here we present a case where EUS FNA was responsible for a major change in the diagnosis.

PATIENT HISTORY AND PROCEDURE

This 65-year-old female presented with complaints of pain in the right upper abdomen for one year and jaundice for one month. She also had a history of fever off and on, anorexia and weight loss. On general examination she had a pulse rate of 90/mt and her blood pressure was 120/80mm hg. She had icterus and her systemic examination revealed a distended abdomen with a hepatomegaly of 4cms.

She had previously been evaluated at another hospital and had been diagnosed as having disseminated pancreatic carcinoma on the basis of ultrasound and contrast-enhanced computed tomography (CECT) findings. Her abdominal ultrasound revealed intrahepatic biliary radical (IHBR) and common bile duct dilatation toward the lower end (**Figure 2**). A mass was seen in the region of the head of the pancreas and there was mild ascites present. A CECT confirmed the findings of her abdominal ultrasound (US) and also reported multiple small lymph nodes at the porta.

She was referred to our hospital for an endoscopic retrograde cholangiopancreatography and metallic stent placement followed by palliative chemotherapy, since she was thought to have disseminated pancreatic malignancy.

Investigations done at our center revealed an s. bilirubin of 5.6mg/dl, AST 76IU/dl, ALT 76IU/dL, and alkaline phosphatase of 776 u/dl. Her HB% was 7.6mg% and TLC was 20,000.

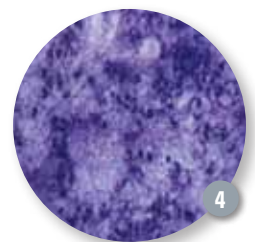
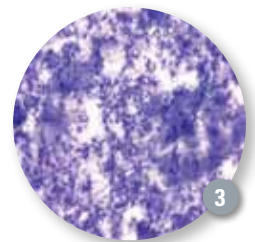
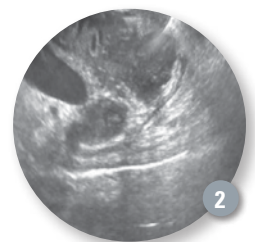
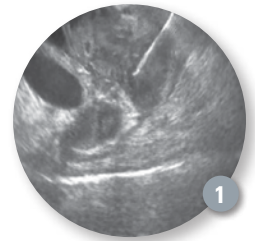
In view of the long duration of illness, and because the patient appeared very well preserved for pancreatic malignancy, an EUS-guided FNA was planned.

The EUS findings were that the IHBR and common bile duct (CBD) were dilated, and there was a mass at the lower end of the CBD, but it appeared to be a conglomerate of lymph nodes (**Figure 1**). There was mild ascites present but the ascitic fluid had multiple strands suggestive of an exudative ascites. An EUS-guided FNA was done using a 22 gauge Expect™ EUS-FNA Needle. Pus-like material was obtained and cytology revealed chronic inflammation and Ziehl-Neelsen staining showed acid fast bacilli (**Figures 3, 4 and 5**).

The patient was diagnosed as having disseminated tuberculosis. A four-drug Antituberculous Therapy (ATT) was started and at last follow up, three months after the ATT, she was doing well, afebrile, free of pain and her s. bilirubin was down to 2.2mg/dl.

DISCUSSION

Abdominal tuberculosis is known to masquerade as malignant abdominal masses. Treatment of benign conditions with stenting and chemotherapy can result in disastrous physical as well as psychological problems for the patient; hence, a tissue diagnosis is mandatory before treating for cancer. Endoscopic ultrasound FNA has an edge over other modalities like CT scan or abdominal EUS-guided FNA due to the proximity of the EUS probe to the lesion and its intraluminal location. **EUS FNA has helped to definitively diagnose a number of conditions which were earlier considered to be out of reach of standard tools for FNA (US, CT).**



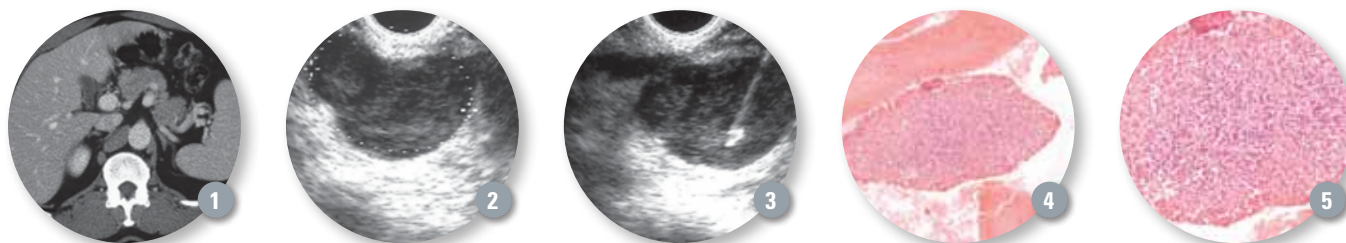
Acquisition of Pancreatic Tissue Using EUS FNA Leads to Diagnosis of Intra-Pancreatic Accessory Spleen



CASE PRESENTED BY:

FAUZE MALUF-FILHO, M.D.

Cancer Institute
Department of Gastroenterology of
São Paulo University
São Paulo, BRAZIL



PATIENT HISTORY AND ASSESSMENT

A 46-year-old male was referred for tissue sampling of a mass located at the pancreatic tail. The patient was asymptomatic. He presented a familial history of gastrointestinal neoplasms and was submitted for a computerized tomography scan. A 2cm, solid, round nodule was detected at the tail of the pancreas (**Figure 1**). The margins were regular and clearly demarcated. The lesion was enhanced after contrast injection. A presumptive diagnosis of a non-functioning neuroendocrine tumor (NFNET) was made. Considering that conservative treatment is considered for small pancreatic NFNETs with low expression (<2%) of ki-67, a tissue sample was indicated.

PROCEDURE

Using endoscopic ultrasound (EUS), a round solid nodule was easily defined at the pancreatic tail (**Figure 2**). There were no lymph nodes, signs of vascular invasion or ductal dilation. Endoscopic ultrasound fine-needle aspiration (FNA) was performed with a 22G Expect™ EUS-FNA Needle. The tip of the needle was clearly observed on an echogenic image (**Figure 3**). Several core fragments of the tumor were obtained after three passes under vigorous suction.

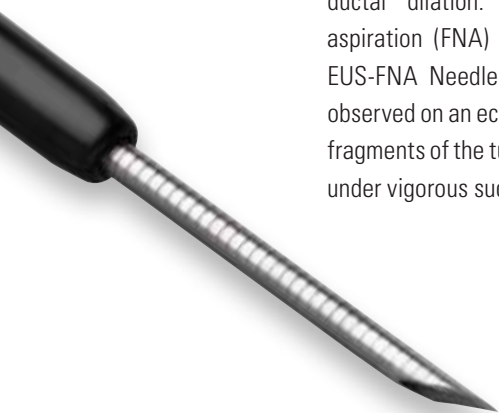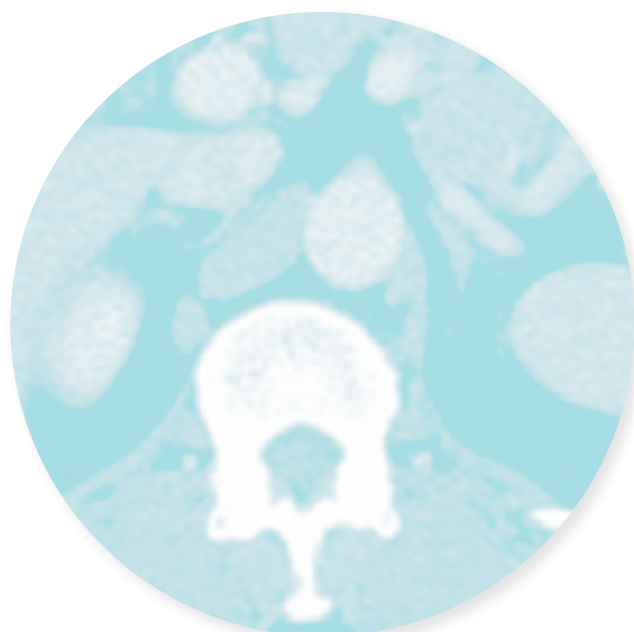PATIENT OUTCOME AND RESULTS

The histopathological findings were consistent with splenic tissue and the final diagnosis was intra-pancreatic accessory spleen (**Figures 4 and 5**).

SUMMARY AND DISCUSSION

Solid pancreatic incidental nodules should be considered highly suspicious for malignancy (i.e., adenocarcinoma, neuroendocrine tumors). Taking this fact into consideration, some groups advocate surgical resection whenever possible even without previous histology. On the other hand, one should keep in mind the possibility of an intra-pancreatic accessory spleen when a small solid nodule is found at the tail of the pancreas in an asymptomatic patient.

Endoscopic ultrasound FNA is the gold standard method for acquisition of pancreatic tissue.



Resolution Clip Facilitates Endoscopic Hemostasis, Improving Visibility and Access to Bleeding Vessel



CASE PRESENTED BY:

SERGEY V. KANTSEVOY, M.D., PH.D

The Melissa L. Pozner Institute for Digestive Health and Liver Disease at Mercy Medical Center
Baltimore, Maryland, USA

PATIENT HISTORY

A 74-year-old woman with multiple medical problems (hypertension, diabetes mellitus, coronary artery disease, chronic renal insufficiency on hemodialysis) became weak, dizzy and lost consciousness at home. She was brought to the emergency room by ambulance and was found to have anemia (Hematocrit = 22). An emergency upper endoscopy revealed an ulcerated mass 2 by 3cm inside the stomach (**Figure 1**). Because the risk of recurrent bleeding from the ulcerated gastric lesion was high, she was referred to us for endoscopic resection of the lesion.

DESCRIPTION OF PROCEDURE

An endoscopic ultrasound was performed and demonstrated hypoechoic rounded gastric lesions located in the submucosal layer of the gastric wall with a clearly seen large vessel inside the lesion (**Figure 2**). To prevent the bleeding from this vessel, a PolyLoop™ Snare was applied to the base of the lesion. However, after the lesion was resected with a snare, the PolyLoop Snare fell off and a severe arterial bleed started (**Figure 3**).

Unfortunately, the bleeding vessel was located under the mucosal margin of the incision and it was impossible to visualize and to access this vessel for hemostasis. In this situation, we applied one Resolution™ Clip to the site of the vessel's origination. Application of

the clip slowed down the bleeding but, more importantly, it pulled the mucosal margin away and clearly demonstrated the origin of the bleeding vessel (**Figure 4**). Then the definitive hemostasis was easily achieved (**Figure 5**).

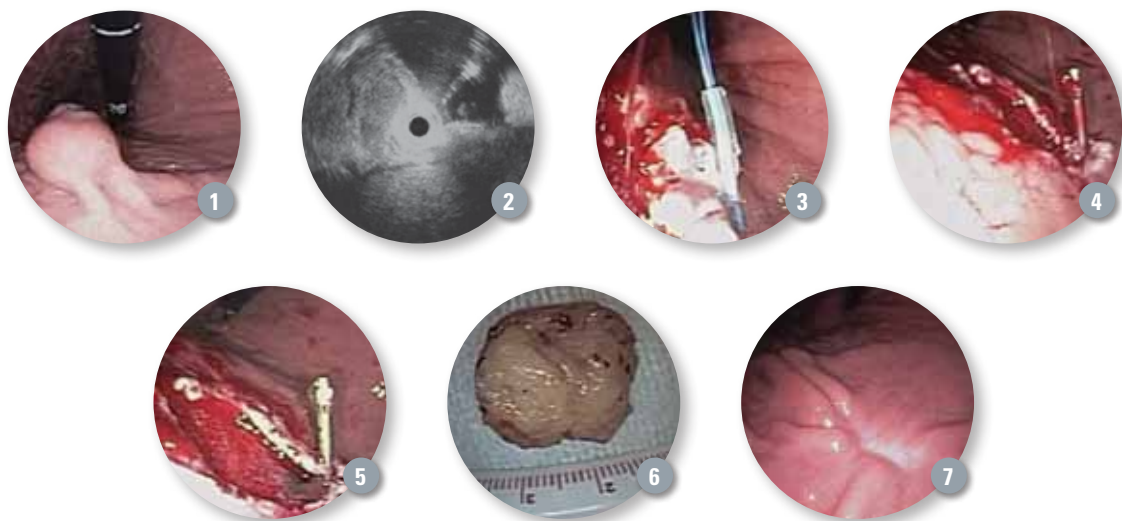
OUTCOME AND POST-PROCEDURE

The pathological examination of the removed lesion (**Figure 6**) revealed a gastric carcinoid. The patient tolerated the procedure well and was discharged home two days after endoscopy in stable condition.

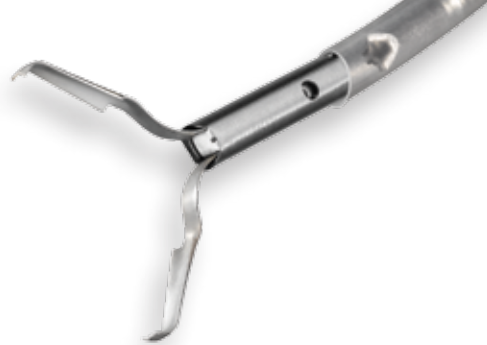An upper endoscopy was repeated in three months and demonstrated a well healed scar at the site of the endoscopic mucosal resection without any remaining carcinoid tissue (**Figure 7**). The patient did not have any other episodes of gastrointestinal bleeding.

CONCLUSION

This case demonstrates additional value of the Resolution™ Clip in difficult cases of endoscopic hemostasis. If the bleeding vessel cannot be directly approached initially, application of the Resolution Clip can slow the rate of bleeding and may alter the local anatomy, providing favorable conditions for definitive endoscopic hemostasis.



Endoscopic Mucosal Resection is Used for Polypectomy; Resolution Clips Close the Defect



CASE PRESENTED BY:
RAJESH N. KESWANI, M.D.
Assistant Professor of Medicine
Northwestern University Feinberg
School of Medicine
Chicago, Illinois, USA



DAVID J. BENTREM, M.D., M.S.
Associate Professor of Surgery
Northwestern University Feinberg
School of Medicine
Chicago, Illinois, USA

PATIENT HISTORY AND ASSESSMENT

A 55-year-old female presented for a surveillance colonoscopy to her primary gastroenterologist. During the surveillance colonoscopy, a 25mm non-polypoid (Paris O-Ia) lesion was seen in the mid-ascending colon and was biopsied to be a tubular adenoma (**Figure 1**). She was referred to a therapeutic endoscopist for an endoscopic mucosal resection.

DESCRIPTION OF PROCEDURE

As the polyp was predominantly located on a proximal fold of the ascending colon, visualization was best in retroflexion from the cecum (**Figure 2**). A submucosal lift was achieved with saline mixed with indigo carmine. Excellent lift of the polyp was noted as can be seen in **Figure 3**. The majority of the polyp was resected using a polypectomy snare and cutting current.

A 10mm perforation was immediately noted after resection with a “target sign” (linear non-staining of the indigo carmine, **Figure 4**). As the patient was clinically well, the remainder of the polyp was first removed and then attention was paid to closing the defect. While maintaining scope position, five Resolution™ Clips were deployed to

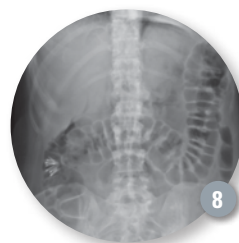
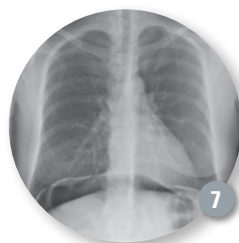
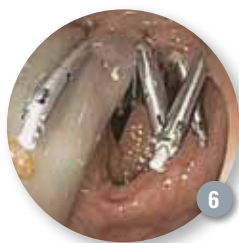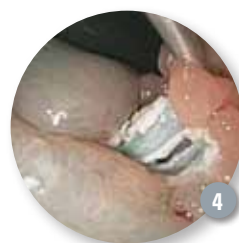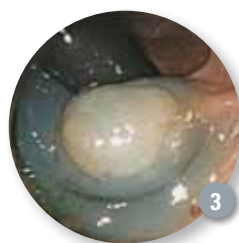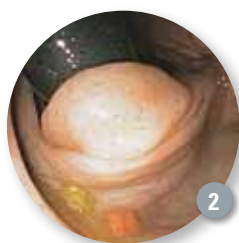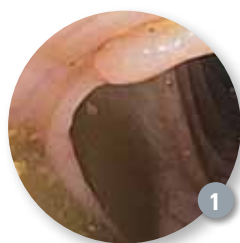completely close the perforation (**Figure 5**). In forward view, three additional Resolution Clips were placed to fully close the remaining post-polypectomy defect (**Figure 6**).

OUTCOME

The patient was admitted to the hospital and was made nil per os (NPO) with intravenous antibiotics. Surgical consultation was obtained with an agreement for an attempt at non-operative management. She experienced mild pain that did not require analgesia on the first day.

An abdominal x-ray was obtained on the second day of hospitalization and demonstrated marked free intra-peritoneal air (**Figure 7**). All eight Resolution Clips remained in place in the ascending colon (**Figure 8**).

A computed tomography scan with oral contrast was performed on day three and showed no leakage of contrast at the polypectomy site and a slight reduction in intra-peritoneal air. Based on these findings and her clinical wellness, an oral diet was resumed and she was discharged.



Endoscopic Mucosal Resection for a Large Polyp Removal



CASE PRESENTED BY:
MANKANWAL SACHDEV, M.D.
 Mercy Gilbert Medical Center
 Gilbert, Arizona, USA

PATIENT HISTORY

A 55-year-old male with a prior history of colon polyps underwent a recent colonoscopy, which revealed a 2.5cm flat polyp (**Figure 1**). Biopsies showed a tubulovillous adenoma. Surgery was recommended but the patient sought a second opinion in regard to endoscopic mucosal resection.

PROCEDURE

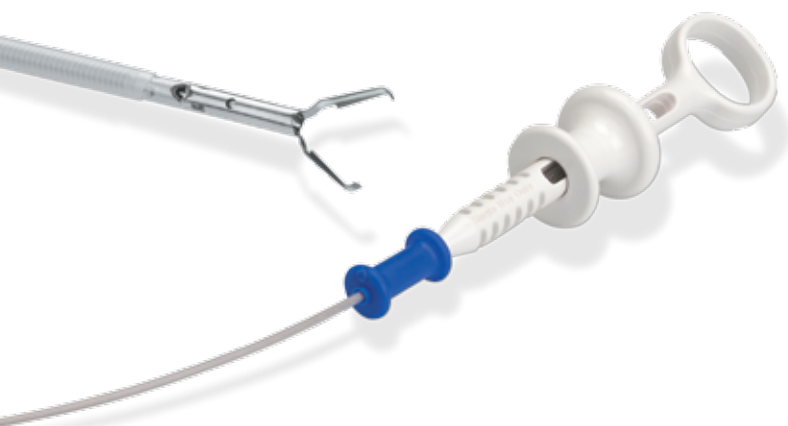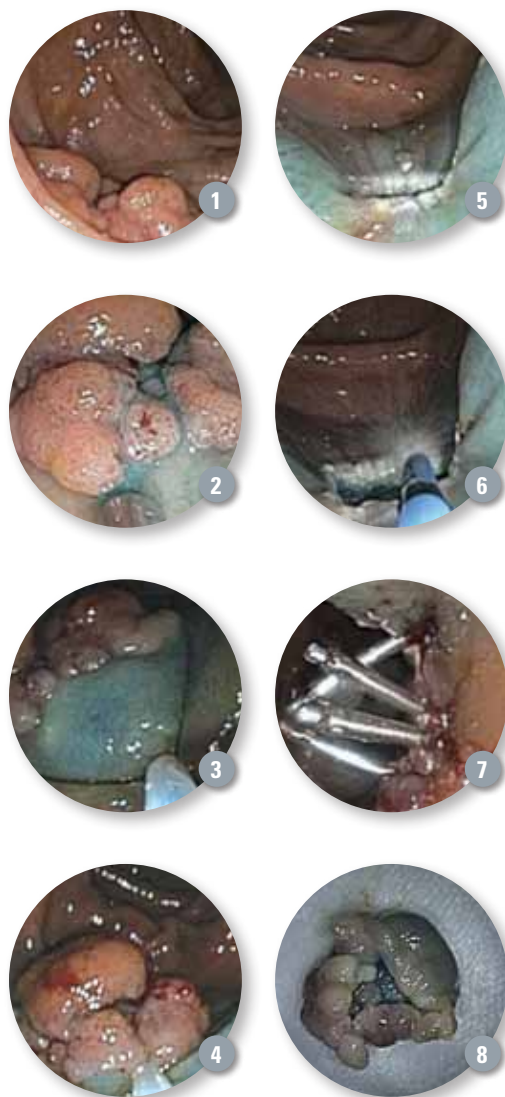
The patient underwent a repeat colonoscopy with the intent to perform an endoscopic mucosal resection (EMR). As previously noted, the polyp was flat and large. Normal saline was prepared with a few drops of methylene blue added to achieve a light-aqua blue color. Using 20cc of this solution, the polyp was lifted (**Figure 2**). Following this, a 33mm Captivator™ II Snare was used to grasp the polyp in one piece (**Figure 3**). Using standard electrocautery settings, the polyp was resected in one piece (**Figures 4 and 5**). Argon plasma coagulation was then used to cauterize the edges of the polyp so that the chances for regrowth would be diminished (**Figure 6**). Four Resolution™ Clips were applied to the resulting mucosal defect, which was approximately 2cm in size (**Figure 7**). Finally, the polyp was recovered using the TWISTER® PLUS Rotatable Retrieval Device (**Figure 8**).

OUTCOME AND POST-PROCEDURE

Following the procedure, the patient did well with no post-polypectomy bleeding or signs of perforation. He was discharged the same day, and a relook endoscopy was done three months later, which showed healing of the polyp site.

CONCLUSION

Endoscopic mucosal resection is fast becoming the treatment of choice for large polyp resection, and is a good and less expensive alternative to surgery. Because the risk of bleeding was high, I decided to place Resolution Clips. The Resolution Clip is ideal for this scenario due to its 11mm jaw opening and the fact that it can open and close prior to being deployed.





Close the Gap Activities Help Organizations Fund Life-Saving Initiatives

Although Colorectal Cancer Awareness Month has come and gone, Boston Scientific's Close the Gap team continues to sponsor regional events and programs to generate awareness about colorectal cancer. In August, the team sponsored the Colon Cancer Prevention Project's "Walk Away from Colon Cancer and 5K" as well as the organization's pledge program. This program involves the distribution of pledge cards to high-risk individuals in the Louisville, Kentucky area and asks them to commit to getting screened, talking with their family about family history and sharing with others the importance of screening. The group is also participating in the Colon Cancer Alliance's regional "Undy 5000" 5K races throughout the rest of the year.

In March, the team raised \$20,000 that was donated to the Colon Cancer Alliance. The money is being used to develop a new screening-assistance program that the Colon Cancer Alliance plans to launch in spring 2014. "The money donated by Boston Scientific will be used so that individuals who could not otherwise afford to do so are able to undergo this potentially life-saving screening," said Interim Chief Executive Officer of the Colon Cancer Alliance Jasmine Greenmyer.

The Close the Gap team is also raising funds and educating individuals about pancreatic cancer and the importance of supporting research to find a cure. For the second year, the group formed a team of Boston Scientific employees to walk in the "Unite to Fight Pancreatic Cancer" event held at Mother's Rest Park in Boston, Massachusetts on September 28. The team is also planning to host educational and fundraising activities throughout November in support of Pancreatic Cancer Awareness Month.

Boston Scientific's Close the Gap is an ongoing program focused on initiatives to eliminate treatment disparities for high-risk, underserved patient populations suffering from gastrointestinal and pulmonary diseases by increasing awareness, sponsoring and developing educational programs and improving access to care.

To learn more about how you can get involved with colorectal and pancreatic cancer awareness activities, please visit:

- › The Colon Cancer Alliance website: www.ccalliance.org or free Helpline (877) 422-2030
- › The Colon Cancer Prevention Project website: www.coloncancerpreventionproject.org
- › The Lustgarten Foundation website: www.lustgarten.org

News and New Devices

➤ In September, Boston Scientific opened the China branch of the **Boston Scientific Institute for Advancing Science** as well as its new **Innovation Center** in Shanghai, China. Through these state-of-the-art facilities, Boston Scientific expects to foster local talent while sustainably developing innovative technology uniquely suited to the China market. The Innovation Center is designed to drive understanding of innovative technologies and advanced medical technology products. The Center is fully equipped with the latest multimedia devices, demonstrating the company's cutting-edge research in disease treatment practices.

➤ The **NaviPro™ Hydrophilic Guidewire** is a 100 percent hydrophilic guidewire designed for cannulation and smooth passage through tortuous anatomy. **See case study on p. 8.** View a demonstration of the hydrostatic technique by Dr. David Carr-Locke, Beth Israel Medical Center, New York, NY.

➤ **TWISTER® PLUS Rotatable Retrieval Device** is a three-dimensional net that is fully rotatable and designed to facilitate polyp, food bolus and foreign object retrieval. **See case study on p. 16.**

View videos at
www.bostonscientific.com/endo-resources and select Videos.



New Section of Website Organizes Information by Treatment Options and Key Technologies



Now available on its Endoscopy Resources website, Boston Scientific launched a new Treatment Options section organized in a way that clinicians would typically search so information can be found quickly and easily. The Endoscopy Resources website provides information on a wide range of diagnostic and therapeutic options for managing over 100 gastrointestinal diseases and conditions.

Physician case studies, procedural videos and presentations, clinical summaries and perspectives as well as general product and ordering information are available.

To Learn More:
www.bostonscientific.com/endo-resources
and click on the Treatment Options tab.

As Seen In

**Gastroenterology
& Endoscopy News**

ACCESS Magazine was produced in cooperation with several physicians. The procedures discussed in this document are those of the physicians and do not necessarily reflect the opinion, policies or recommendations of Boston Scientific Corporation or any of its employees.

Results from case studies are not predictive of results in other cases. Results in other cases may vary.

CAUTION: The law, including Federal (USA) law, restricts these devices to sale by or on the order of a physician. Indications, contraindications, warnings and instructions for use can be found in the product labeling supplied with each device.

WARNING: The safety and effectiveness of the WallFlex Biliary Stent for use in the vascular system has not been established.

Captivator, Enhancing patient outcomes. Delivering Total Value., Expect, Jagwire, NaviPro, Radial Jaw, Resolution, SpyGlass, and WallFlex are registered or unregistered trademarks of Boston Scientific or its affiliates. TWISTER® PLUS is a trademark of Horizons International Corp. Distributed by Boston Scientific Corporation, Natick, Massachusetts; manufactured by Horizons International Corp., Heredia, Costa Rica. All other trademarks are property of their respective owners.

©2013 Boston Scientific Corporation or its affiliates. All rights reserved.

DINEND2317EA

ENDO-187304-AA October 2013

**Boston
Scientific**