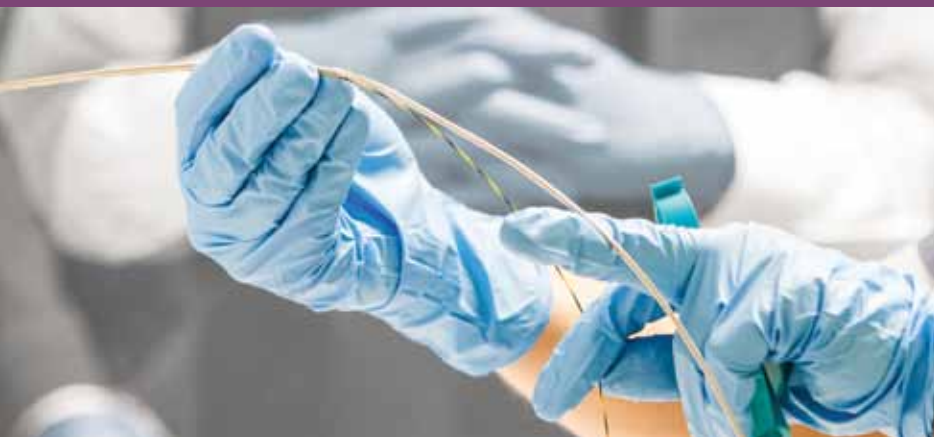

access

ENHANCING PATIENT OUTCOMES. DELIVERING TOTAL VALUE.™



Nurse Education Gains Momentum

Boston Scientific brings a wide range of development opportunities to nurses.

A Message From Dave Pierce

Awareness, Education — Powerful Tools for Improving Patient Outcomes

In 2013 close to 143,000 people in the U.S. will be diagnosed with colorectal cancer. Of those, more than 50,000 will ultimately die from this disease. Early detection has been shown to improve survival rates; at least six out of every ten deaths from colorectal cancer could be prevented if all men and women aged 50 years and older were screened routinely. In March, during colorectal cancer awareness month, Boston Scientific did its part to call attention to this important cause (read more on p. 17). By making people aware of the disease and treatment options, today, there are more than one million who beat cancer to tell their survival stories.

Whether it's our work for colorectal cancer, the work we've done in support of the Lustgarten Foundation*



Dave Pierce presents at the Endocon conference held in Hyderabad, India, March 2013.

for pancreatic cancer or the work we do together with physicians, hospitals and societies every day, we know that education is helping save lives. We also know that when it comes to education and training, it takes a variety of

approaches and methods to enhance patient outcomes and deliver total value.

India is a great example. Our India team has expanded its Endoscopy Gurukul (school) to include both "brick and mortar" centers at leading hospitals as well as virtual training centers with procedural videos and educational materials. Currently, more than 400 physicians have registered with the Endoscopy Gurukul. In February, we helped sponsor the World Endoscopy Organization's first of its kind program in Hyderabad, India, designed to train senior physicians to teach endoscopy trainees in residency or fellows programs.

Working with the American Society of Gastrointestinal Endoscopy, we sponsored a program to bring training to 29 physicians in Brazil and at the same time brought care to over 100 patients in a remote region of the Amazon (p. 4). For nurses in the U.S., we are partnered with the Society of Gastrointestinal Nurses Association and have sponsored and helped develop a variety of programs (p. 3). We developed our own nurses

Professional Development Program that was originally launched in Europe and is being customized and implemented in South America and countries in Asia Pacific (p. 2).

So much of what we do is about helping clinicians share best practices. It's always been a focus for us and we're continuing to develop different ways to make this information available globally. In the fall, our team in Japan launched its own YouTube™ Channel, and viewers from 30 countries tuned in to watch a live webcast that we conducted with question and answer sessions on endoscopic ultrasound fine needle aspiration.

Of course, we know we need to keep learning as well. It's critical for us to understand the changing needs and priorities of the industry — one of which is the call for "green" solutions. As a result, we are focused on taking a more sustainable approach to what we do. In recent months we made packaging improvements to several products and in the process reduced package weights, ensured we were using recyclable materials whenever possible and made strides in decreasing what goes into waste streams (p. 5).

In this issue you can also learn about our new clinical study to prove the efficacy of metal stents for preoperative biliary drainage (p. 8). And once again we have a good variety of cases submitted from around the globe, including an interesting case on our new TRUetome™ Cannulating Sphincterotome from physicians at Swedish Medical Center in Seattle, Washington.

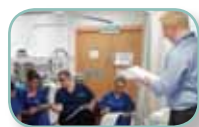Dave Pierce

Senior Vice President, Boston Scientific
President, Endoscopy Division

*To learn more visit, www.lustgarten.org

Inside This Issue

Articles



2 A Commitment to Education Includes Development for Endoscopy Nurses



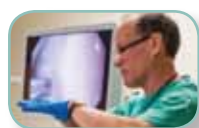3 Boston Scientific Helps Launch First Annual Nurses Training Program at Swedish Medical Center



4 Philanthropic Program Brings Medical Care and Physician Training to a Remote Region of Brazil



5 Packaging Improvements Make a Difference: Changes Focus on Sustainability and Efficiency



6 University of Colorado School of Medicine Hosts Interventional Endoscopy Course



7 Jejunal Feeding Tube Helps Gastroparesis Patient Return to Active Lifestyle



7 Annual Health Economics & Reimbursement Webinar Helps Keep Customers Informed



8 First Patient Enrolled in Study to Prove Efficacy of Metal Stents for Preoperative Biliary Drainage



17 Boston Scientific 'Joins the Fight' Against Colorectal Cancer




18 Nothing 'Lost in Translation' for Coyal Facility Employees



18 Resolution™ Clip Now has Magnetic Resonance Conditional Claim

Case Studies



9 TRUEtome™ Cannulating Sphincterotome



10-12 WallFlex™ Stents



13-15 Expect™ Needle for EUS FNA

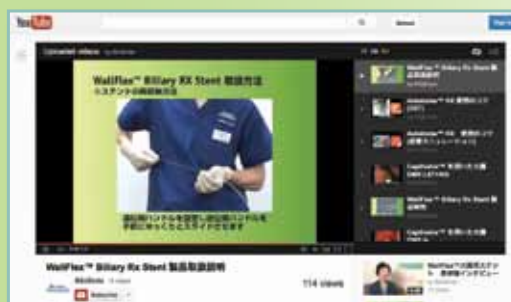

16 SpyGlass™ Direct Visualization System

Online Global Resources

New. In January 2013, Boston Scientific launched its Endoscopy Channel on YouTube™ in Japan.

Visit: www.youtube.com/user/BSJEndo



For the latest news and information from Boston Scientific Endoscopy, visit www.bostonscientific.com/endo-resources.



Nurses participate in training held at Alexandra Hospital, Redditch, England.

A Commitment to Education Includes *Development for Endoscopy Nurses*

Boston Scientific recently launched, in Europe, its Professional Development Program (PDP), a platform of training modules designed to further advance the clinical and technical knowledge of endoscopy nurses and technicians. To date, in more than 12 countries throughout Europe, 2,500 nurses and technicians have participated in more than 300 sessions. Training sessions have also been conducted on both a country and regional level in Asia Pacific and South America. The Program is endorsed by the European Society of Gastroenterology and Endoscopy Nurses and Associates (ESGENA).

“Continuing education is an essential tool in maintaining a good clinical practice and improving the quality of patient care in endoscopic nursing.”

— **Ulrike Beilenhoff**
ESGENA Scientific Secretariat

“Continuing education is an essential tool in maintaining a good clinical practice and improving the quality of patient care in endoscopic nursing,” said Ulrike Beilenhoff, ESGENA scientific secretariat. “In addition to the technical information, clinical education is also important for nurses. Having this knowledge helps nurses better understand the product, support physicians during procedures and improve their safe practices. Boston Scientific’s professional development program helps address these needs.”

Currently three training modules are available and are designed to enable learning within the field of tissue acquisition, hemostasis and gastrointestinal (GI) dilation. Each module consists of four chapters: pathology, procedures, products and practical. The format is flexible so that it can be completed in one training session or multiple sessions, and can be used as a refresher program and a resource once completed. Training is conducted by a Boston

Scientific instructor. On completion of each module, participants are given a handbook along with a comprehensive knowledge check and a certificate of completion is issued.

“This training increases our nurses’ confidence and allows them to practice their skills outside of the procedure room. Having a certificate of completion is an added benefit. It’s proof of their continued education and something they can use in their career development,” explained Nurse Manager Jo Fox, Worthington Hospital, West Sussex, United Kingdom.

In addition to its PDP, Boston Scientific continues to support the training of nurses and technicians through support of societies throughout the world, including the Society of Gastroenterology Nurses (SGNA), the Gastroenterological Nurses College of Australia and the World Endoscopy Organization.

3

TRAINING
MODULES

1 Tissue Acquisition

2 Hemostasis

3 Gastrointestinal Dilation

ADDRESSING NON-CLINICAL SKILLS

In addition to advancing clinical knowledge and technical hands-on training, with sponsorship from Boston Scientific, the SGNA implemented a program for nurses in the U.S. to develop their presentation skills. Since 2011, three of the "Present with Success" programs have been held in conjunction with SGNA leadership conferences. The program includes a one-day, highly interactive session that focuses on meeting the educational needs of nurses looking for management, leadership and professional development content. A pre-program webinar is also available to maximize individual coaching during the training.

Boston Scientific and the SGNA have other development initiatives underway in 2013, including a formal nurse mentoring program. "SGNA is excited to develop a nurse manager mentoring program that will help meet the needs of our members. We are thrilled that Boston Scientific has agreed to support this program as an evolution of the leadership and management programs they have supported over the years," said President of the SGNA, Phyllis Malpas, MA, RN, CGRN.

At the 2013 SGNA Leadership Conference, Boston Scientific will once again take part in the Vendor Forum Programs. Participating for the third time, Boston Scientific sponsored sessions include two clinically focused sessions on treatment options for GI bleeding and best practices in endoscopic ultrasound fine needle aspiration, as well as a session on reimbursement and economics for operational excellence. Continuing Education Credits are given for the sessions.

In the U.S., local representatives facilitated more than **14,500** nurse and technician training programs with close to **125,000** continuing education units distributed over the last five years.



You're invited to Vendor Programs at the SGNA 40th Annual Course

RECEIVE YOUR CE CREDITS

- 2013 Reimbursement and Economics for Operational Excellence
- Current Treatment Options for GI Bleeding
- Best Practices and Future Trends in EUS Cytopathology

Enhancing patient outcomes. Delivering total value.
It's where your life's work meets ours.

Boston Scientific Helps Launch First Annual Nurses Training Program at Swedish Medical Center

Swedish Medical Center held its first annual **Advanced Therapeutic Endoscopy training for nurses**, January 26, 2013, at the Swedish Medical Center's First Hill Campus in Seattle, Washington. More than 200 nurses and technicians from Alaska, Idaho, Montana, Oregon and Washington attended the day of training that included didactic presentations from Swedish Medical Center physicians and nurses, and hands-on training facilitated by Boston Scientific representatives. In addition, several round table discussions on advanced technologies were held in the afternoon where discussions focused on hemostasis, metal stenting, ERCP and interventional pulmonology procedures.

"Boston Scientific was instrumental in helping us organize this event for GI nurses," said Dr. Jack Brandabur of Swedish Medical Center.

"We look forward to working with them on similar events in the future as training for nurses remains a top priority."

"Boston Scientific was instrumental in helping us organize this event for GI nurses."

— Dr. Jack Brandabur
Swedish Medical Center

Philanthropic Program Brings Medical Care and Physician Training to a Remote Region of Brazil

The American Society of Gastrointestinal Endoscopy (ASGE) in collaboration with the Brazilian Society of Digestive Endoscopy conducted its sixth Ambassador Program in Manaus, Brazil, a state of the Amazon. Boston Scientific and other sponsoring members provided financial and in-kind support for the program.



Boston Scientific employees help prepare training stations.

During the six-day event in December 2012, 29 local physicians trained in the diagnosis and endoscopic treatment of a variety of gastrointestinal (GI) diseases but with an emphasis on esophageal varices – a condition common to this particular underserved region. During the three days of procedures more than 100 patients were treated.

“The ambassador program is a great example of industry-society collaboration and using a mix of international and local resources to address an important issue,” said Dr. Qjang Cai, Emory University School of Medicine, Atlanta, Georgia. “Together we were able to treat patients who would normally not have access to this type of care, and at the same time we are able to educate and train local physicians so they may continue to diagnose and treat diseases that are managed successfully every day in many other regions of the world.”

Two U.S. physicians and two physicians from Brazil served as ASGE Masters. Dr. Ian Gan, of Virginia Mason Medical Center, Seattle, Washington; Dr. Qjang Qjang Cai; Dr. Angelo P. Ferrai, Jr. of Hospital Albert Einstein, Sao Paulo; and Dr. Ricardo Dib of Hospital Ipiranga of Sao Paulo; conducted didactic sessions and hands-on

training for local physicians whose practices have not traditionally focused on GI technologies and treatment. Dr. Dib also served as the local organizer of the program. The training, which took place at the School of Medicine of the State University of Amazonas, Adriano Jorge Hospital in Manaus, included: band ligation, sclerotherapy, percutaneous endoscopic gastrostomy, endoscopic mucosal resection, dilatations, foreign bodies, clipping, endoloops and argon plasma coagulation.

Ana Ruggie, global interactions manager, Boston Scientific’s education and training group, who travelled to Manaus for the training commented, “I’m grateful for the opportunity to have seen firsthand the impact of this program and to know that Boston Scientific’s support is helping make a difference on a truly global scale.” Through a translator Ruggie was able to speak with patients. She learned that some had travelled for two to three days by boat to receive treatment and for many this was the first procedure of any kind they had undergone.



Boston Scientific employees help with physician training preparations. Left to right: Víctor Siqueira, Alessandra Rincón Moraes dos Santos, Ana Ruggie, Jorge Santos, Alexandre Cruz.


Packaging Improvements Make a Difference

Changes Focus on Sustainability and Efficiency

In recent months, Boston Scientific has put improvement projects in place to make packaging changes to several of its devices. These changes are yielding benefits in the areas of sustainability, procedural efficiency or both.

The footprint of the newly designed package for the **Advanix™ Biliary Stent with NaviFlex™ RX Delivery System** has been reduced by 28 percent. Package dimensions were reduced from 20.75" to 16.25" in length and from 13.5" to 12.5" in width. The new package is a welcome change by nurses and technicians who have to stock devices on a standard-size shelf or pegboard. Now greater quantities can be stocked in the procedure room, making the devices more easily accessible. In addition, the new package supports a more sustainable approach as it uses **23 percent less material than the previous package** and is fully recyclable.

Boston Scientific's Coyol facility in Costa Rica is the largest manufacturer of single-use biopsy forceps in use at hospitals around the world. The Coyol plant is an ISO -14001 and LEED certified facility, and has received recognition for its many environmental initiatives.



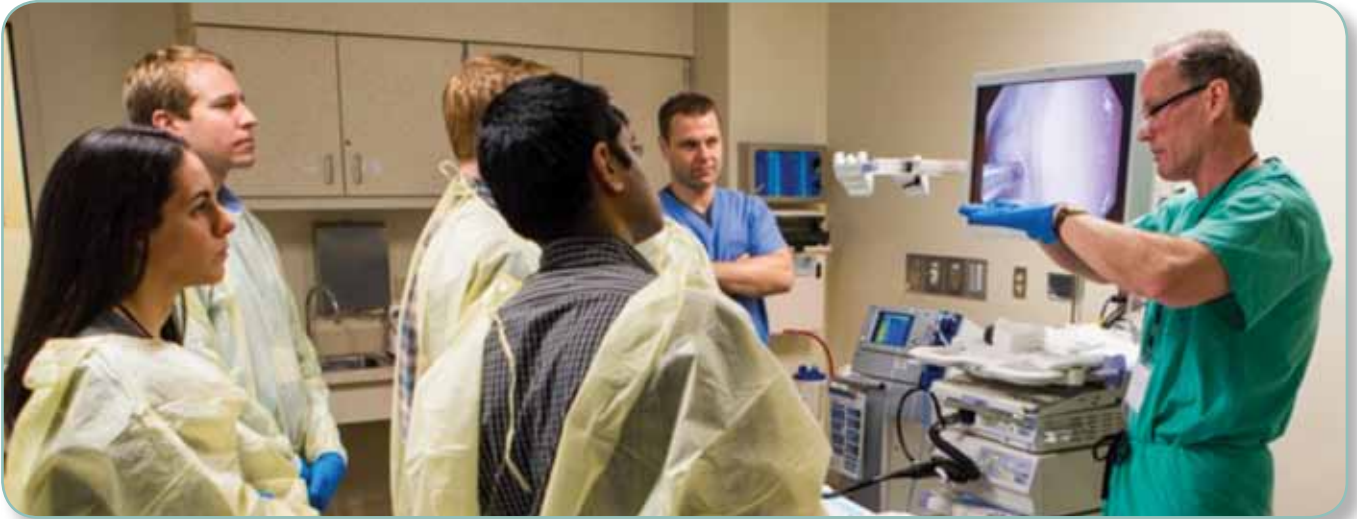Another "green" improvement underway is for the **Radial Jaw™ 4 Biopsy Forceps**. A plan is now in place to make the plastic packaging **13.6 percent smaller**, allowing nurses and technicians to keep more devices on the lab cart and spend less time restocking. The corrugated cartons are smaller as well. A Box 5 is **35 percent smaller**; a Box 20 is 39 percent smaller; and a Box 40 is 24 percent smaller. The smaller carton sizes have the potential to help hospitals reduce costs associated with recycling.

An improvement project for the **CRE™ Dilation Balloon** also led to a new packaging solution. Customer feedback on device performance was that the balloon catheter was "tightly wound" within the package and could take additional time to get the device ready for use. As a solution, Boston Scientific added a mounting card to alleviate the need to intertwine the catheter and to hold the device in place. The balloon catheter will now be easier to handle when setting up for a procedure, and the new package is made of fully recyclable REC-2-0 high-density polyethylene.

Customer feedback also played a role in changing how the syringe that is included with the **Expect™ Endoscopic Ultrasound Aspiration Needle** is packaged. For nurses preparing the device, the syringe had to first be rotated to a specific channel (with locking fins) where it could be engaged and locked at a specific cc measurement. As a result of performance feedback from various customers, Boston Scientific was able to quickly develop and implement changes to its packaging and inspection processes to make the syringe easier to use. Now, the syringe tab will be rotated to a chamber with locking fins during packaging so additional rotations are not required during a procedure, saving time and improving procedural efficiency.



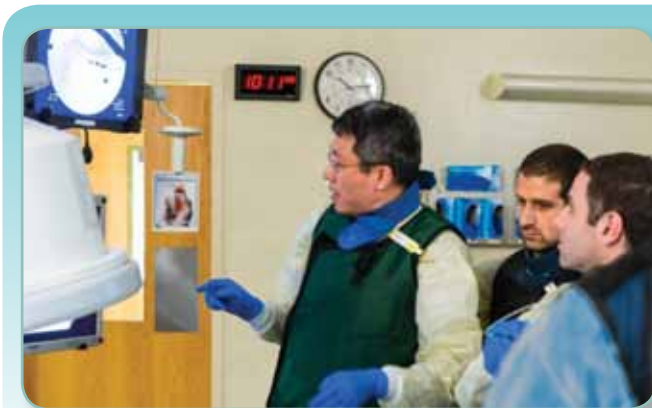University of Colorado School of Medicine Hosts Interventional Endoscopy Course



Dr. M. Brian Fennerty, FASGE and professor of medicine at Oregon Health & Science University, Portland, Oregon, explains hemostasis.

Nearly 300 fellows, nurses and physicians participated in the 10th annual Rocky Mountain Interventional Course (RMIE) held February 13-15, 2013 at the Anschutz Medical Campus, Aurora, Colorado. The three-day RMIE course included a Fellows Advanced Endoscopy and Gastrointestinal Nurses programs and consisted of hands-on animal lab sessions, lectures and televised live cases with an expert physician panel to facilitate discussion.

The program was sponsored by the University of Colorado School of Medicine, Office of Continuing Medical Education, and presented by the University's division of gastroenterology and hepatology. Boston Scientific was the major sponsor of the fellows advanced endoscopy program, and along with other medical device companies sponsored other portions of the program through grants and in-kind support. The next course is scheduled for February 12-14, 2014.



Dr. Tong Jing, Ph.D and assistant professor of medicine at Bellevue Hospital in New York instructs on bile-duct cannulation.



Nurse instructor Rachel Butitta discusses steps for deploying self-expanding metal stents.

Photos courtesy of Rocky Mountain Interventional Endoscopy Course 2013.

Jejunal Feeding Tube Helps Gastroparesis Patient *Return to Active Lifestyle*

For several years **Amanda Singer** struggled to manage the complications of Gastroparesis, a condition that slows or stops the movement of food emptying from the stomach to the small intestine. In 2011 Amanda was 30 pounds underweight, exhausted, and in and out of emergency rooms. She had tried a few different jejunal feeding tubes that did not work effectively for her as they did not remain in place.

While attending a conference to seek alternative solutions for her condition, Amanda learned about the EndoVive™ Through-The-PEG Jejunal Feeding Tube from Boston Scientific and about the gastrointestinal team of physicians at Beth Israel Deaconess Medical Center in Boston, Mass. In 2012, Amanda had an EndoVive Through-The-PEG Jejunal Feeding Tube placed in her jejunum. In order to help ensure the secure placement of the feeding tube, physicians used a Resolution™ Clip as part of the placement procedure.

“Without my Boston Scientific J-Tube I honestly don’t know if I would be alive. As my primary source of nutrition and hydration, and a way to receive much needed medication, it allowed me to regain my strength and get back to a more normal life,” said Amanda. The EndoVive Feeding Tube helped Amanda return to her active lifestyle that included performing aerial yoga, dancing, swimming and pursuing a college degree.



“Without my Boston Scientific J-Tube
I honestly don’t know if I would be alive.”

Annual Health Economics & Reimbursement Webinar Helps Keep Customers Informed



In December 2012, Boston Scientific held its 4th annual complimentary reimbursement webinar to communicate gastrointestinal (GI) coding and reimbursement changes in 2013 for U.S. health care practices and facilities. Guest speaker Glen Littenberg, M.D., FACP, chair of the Practice Management Committee and CPT advisor for the American Society for Gastrointestinal Endoscopy, reviewed key coding and Medicare payment changes for GI procedures in 2013. Dr. Littenberg discussed and answered questions on health care reform and policy changes impacting gastroenterologists, hospitals and ambulatory surgery centers.

More than 300 individuals – a mix of physicians, coders, nurse managers and administrators— participated in the webinar. Eligible participants were awarded American Academy of Professional Coders continuing education units.

To hear a replay of the webinar or register to receive information for future webinars, visit the Boston Scientific website: www.bostonscientific.com/reimbursement.

REIMBURSEMENT SUPPORT FOR CUSTOMERS

In addition to the annual webinar, throughout the year, assistance is available to customers through the Boston Scientific Endoscopy Reimbursement Help Desk. The Help Desk is a resource for nurses, administrators, physicians and reimbursement professionals seeking a better understanding of reimbursement for procedures utilizing Boston Scientific Endoscopy products on-label.

**Endoscopy Reimbursement Help Desk: 1-800-876-9960
ext. 4145, or endoreimburseshelpdesk@bsci.com.**

First Patient Enrolled in Study

to Prove Efficacy of Metal Stents for Preoperative Biliary Drainage



The first patient has been enrolled in a Boston Scientific-sponsored clinical study comparing no drainage to preoperative biliary drainage using WallFlex™ Biliary RX self-expanding metal stents (SEMS) in patients with resectable pancreatic or periampullary cancer. Professor Guido Costamagna, M.D., from Policlinico A. Gemelli, Rome, Italy, and Professor James Lau from Prince of Wales Hospital, Hong Kong, China, will serve as the lead physician investigators for this worldwide, multi-center prospective randomized study.

The goal of the 294-patient study is to demonstrate the potential benefits of preoperative biliary drainage using SEMS. The study's main measure will evaluate the rate of serious pre-operative, operative and post-operative adverse events up to 120 days after the patient has entered the study.

When managing patients diagnosed with resectable pancreatic cancer or periampullary cancer, the goal is to perform surgery as soon as possible. However, conditions including, jaundice, pain and compromised cardiovascular function may contribute to complications prior to and during surgery. In these cases, drainage may serve as a pre-surgery treatment in order to allow a patient to return to more normal physiological function.

294-patient study

In addition to Policlinico A. Gemelli and Prince of Wales Hospitals, centers currently enrolled to participate include:

Westmead Hospital
AUSTRALIA

Dr. Michael Bourke

ULB Erasme Hospital
BELGIUM

Professor Jacques Devière

Tokyo Medical University
JAPAN

Dr. Takao Itoi

Hospital Edouard Herriot
FRANCE

Professor Thierry Ponchon

Asian Institute of
Gastroenterology
INDIA

Dr. Nageshwar Reddy

University of
Montréal-Saint-Luc Hospital
Hospital Center
CANADA

Dr. André Roy

The WallFlex™ Biliary Stents are not indicated for preoperative biliary drainage.

WallFlex Biliary Stents are indicated for use in the palliative treatment of biliary strictures produced by malignant neoplasms. The WallFlex Fully Covered Stent is also indicated for the treatment of benign biliary strictures in CE Mark countries.

Sphincterotome Steerability Facilitates Stent Placement in Damaged Pancreatic Duct



CASE PRESENTED BY: (Left to right)

DREW SCHEMBRE, M.D.

TRISTAN CASE
3D Fluoro Technician

JACK BRANDABUR, M.D.

Swedish Medical Center
Seattle, Washington, USA

PATIENT HISTORY

This patient is a 22-year-old male referred from an outlying hospital with complaints of abdominal pain. He had been involved in a rollover motor vehicle accident in which he was not wearing a seatbelt. He was ejected from the vehicle in which he was a passenger.

Initial evaluation and care focused on pulmonary contusions and multiple orthopedic issues. Subsequent evaluation of abdominal pain included a computerized tomography scan of the abdomen, which revealed ascites in the abdomen and pelvis, pancreatic edema and a 7cm fluid collection within the lesser sac.

PROCEDURE

The patient underwent endoscopic retrograde cholangiopancreatography at which time a large pancreatic ductal disruption was noted anteriorly over the spine (**Figure 1**). Using 3D fluoroscopy (**Figures 2, 2a, 3, 3a**) and the TRUeTome™ Cannulating Sphincterotome

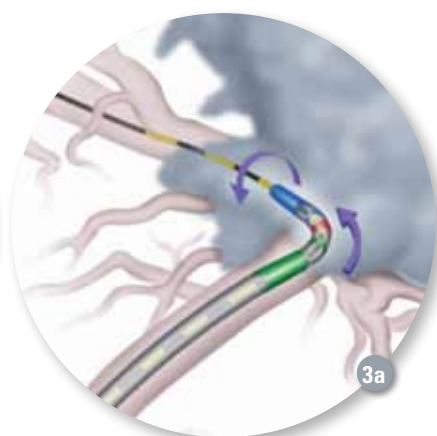
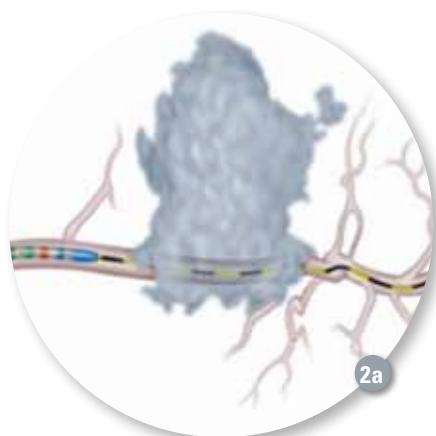
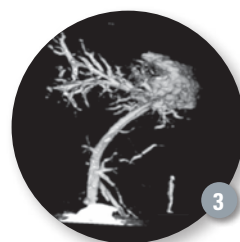
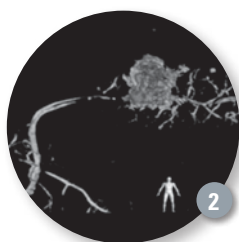
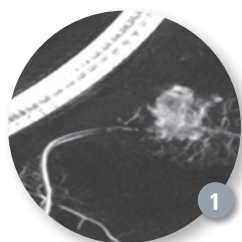
we were able to rotate and orient the Jagwire™ Guidewire such that the upstream pancreatic duct orifice could be localized and accessed. A pancreatic plastic stent was placed across the disruption, sealing the leak.

POST PROCEDURE

The patient also underwent percutaneous drainage of his acute fluid collection. He gradually improved and was discharged home. The combined endoscopic and radiologic therapies obviated surgery.

DISCUSSION

This case represents a pancreatic duct disruption complicating blunt abdominal trauma. The TRUeTome Sphincterotome, coupled with 3D fluoroscopy aided our endotherapy. **The versatility of this new sphincterotome greatly facilitated our efforts in this patient's care.**



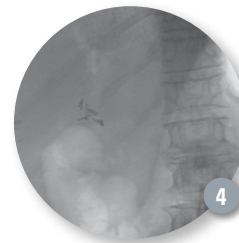
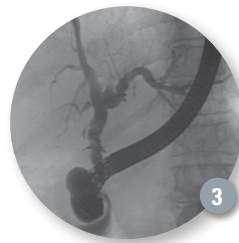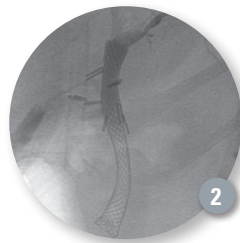
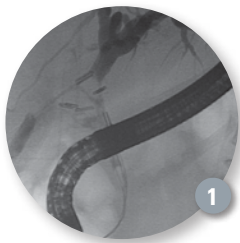
Totally Covered Metal Stent for Post-Surgical Stricture: A New Horizon



CASE PRESENTED BY:

EVERSON L.A. ARTIFON, M.D.

Coordinator of the Pancreatic-Biliary Endoscopy
University of Sao Paulo
Associate Professor of Surgery
University of Sao Paulo
Chief of GI Endoscopy Service, Ana Costa Hospital
Santos, BRAZIL



PATIENT HISTORY

A 67-year-old female patient, with previous history of laparoscopic cholecystectomy was admitted to the emergency room with complaints of upper abdominal pain, fever and jaundice for about nine days. Laboratory data showed a total bilirubin of 12 mg/dl, conjugated bilirubin (8mg/dl) and high levels of GGT (467) and FA (386). Magnetic resonance imaging was performed showing a complex lesion of the choledocho associated with fistula (Bismuth-Blumgart I) and distal biliary stones (**Figure 1**), which clearly was a contributing factor to sustain the fistula.

PROCEDURE

After multidisciplinary evaluation it was decided to submit the patient to endoscopic treatment with passage of a totally covered metal stent (WallFlex™ Biliary RX Stent RMV, 60mm x 10mm) after sphincterotomy followed by biliary stones removal (**Figure 2**). The aim of this was to close the fistula and also promote biliary recanalization. The stent was left in place for four months and it was removed after that time (**Figures 3 and 4**).

DISCUSSION

The endoscopic treatment of postoperative biliary strictures experienced significant development after the introduction of the multi-stent technique, and the use of self-expandable metal stents (SEMS) made it a feasible, efficacious, and less invasive therapy option than surgical treatment. The basic principle of endoscopic therapy consists in the dilation of the stenotic area followed by the placement of a plastic stent to maintain patent the stenotic area with the successive replacement of stents every three months in order to prevent clogging. Thus, we offer to those patients who are not operative candidates the use of totally covered metal stents with excellent radial force in the stricture area. The use of SEMS for biliary benign stenosis should be only in cases with Bismuth-Blumgart I or II; however, we prefer the use of only type I. **In our opinion it was clear that the proximal and distal radiologic markings and the flexibility of the metallic stent facilitated the security of the procedure.**



NOTE: Use of the WallFlex Biliary RX Fully Covered Stent RMV for the treatment of benign strictures or stenoses has not been cleared for use in the United States.

WARNING: The safety and effectiveness of the WallFlex Biliary Stent for use in the vascular system has not been established.

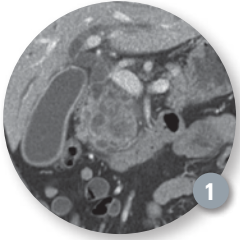
Upfront Covered WallFlex Biliary Metal Stent Insertion in a Patient with Resectable Pancreatic Cancer and Cholangitis



CASE PRESENTED BY:

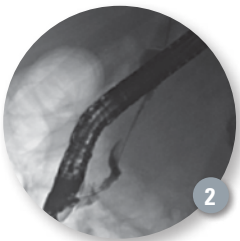
MEHRDAD NIKFARJAM, M.D., PH.D., FRACS

Liver, Pancreas and Biliary Surgeon
University of Melbourne
Department of Surgery Austin Health
Melbourne, Victoria, AUSTRALIA



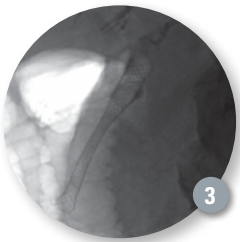
PATIENT HISTORY

A 78-year-old man presented with jaundice, fever and right upper quadrant pain. This was in the setting of significant recent weight loss and new onset diabetes. His total bilirubin was 14.5 mg/dl and white cell count was elevated to 21.0 x 10⁹ /L. Abdominal ultrasound showed a slightly thick-walled distended gallbladder and dilated intra- and extra-hepatic biliary tree. Computerized tomography (CT) confirmed a large pancreatic mass (**Figure 1**). He was treated for cholangitis with intravenous antibiotics and required inotropic haemodynamic support. An urgent endoscopic retrograde cholangiopancreatography (ERCP) was scheduled.



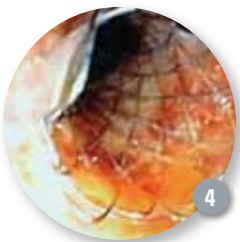PROCEDURE

At ERCP, wire cannulation of the bile duct was achieved using a Jagwire™ High Performance Guidewire 0.035". A tight 4-5cm distal malignant stricture was noted and negotiated with some difficulty using the guidewire (**Figure 2**). Contrast injection was minimized due to the patient's sepsis. A generous biliary sphincterotomy was performed using the Autotome™ RX Cannulating Sphincterotome. Biliary brushings were obtained. Biliary drainage was maximized by placement of a 60mm x 10mm fully covered WallFlex™ Biliary RX Stent (**Figures 3 and 4**). Drainage of turbid bile was noted.



PATIENT OUTCOME

Post procedure, the patient's sepsis and jaundice resolved. Biliary brushing cytology confirmed malignancy. All investigations supported a diagnosis of a potentially resectable pancreatic neoplasm. A pancreaticoduodenectomy was performed six weeks after initial diagnosis, once the patient was well recovered from the episode of severe cholangitis. The common hepatic duct was divided just below the confluence of the right and left hepatic ducts and the metal stent was not encountered. The patient had an uncomplicated recovery and was discharged home seven days following surgery. Final pathology was consistent with a pancreatic cancer arising within a main duct intra-papillary mucinous neoplasia. Nodal metastases were noted in 7 of 23 nodes examined. All resection margins were clear of disease. Adjuvant chemotherapy was commenced five weeks following surgery.



DISCUSSION

Fully covered metal biliary stents are a good option for first-up biliary decompression in the setting of suspected malignant distal bile duct obstruction. Biliary drainage is maximized, with low risk of early stent occlusion. This is particularly important in the setting of resectable peri-ampullary cancers, when surgery needs to be delayed for reasons such as concurrent sepsis or severe jaundice.

Generally, 40mm or 60mm long stents are sufficient to treat distal strictures with the upper end placed well below the confluence of the right and left hepatic ducts. Proximal migration can be reduced by initially partially deploying the upper end of the stent and then pulling the stent down toward stricture prior to further deployment. Acute stent removal at the time of stent placement and new stent redeployment are options in cases when the endoscopist has major concerns regarding stent positioning. Cystic duct occlusion and subsequent acute cholecystitis is an uncommon complication following covered metal stent placement and is also reported following the insertion of bare metal and plastic stents.

With increasing use of neoadjuvant chemotherapy for treatment of resectable peri-ampullary malignancy, the initial placement of a metal stent is important in achieving rapid resolution of jaundice to allow commencement of chemotherapy and to minimise risk of further biliary obstruction.

NOTE: Use of the WallFlex Biliary RX Fully Covered Stent for the treatment of benign strictures or stenoses has not been cleared for use in the United States.

WARNING: The safety and effectiveness of the WallFlex Biliary Stent for use in the vascular system has not been established.

Combined EUS and ERCP for Suspected Pancreaticobiliary Malignancy



CASE PRESENTED BY:

ERIC GANGULY, M.D.

University of Vermont
Burlington, Vermont, USA

PATIENT HISTORY

A 62-year-old woman presented with jaundice, weight loss and pruritus that were progressive over several months. An ultrasound showed dilated intra- and extra-hepatic bile ducts. A follow-up magnetic resonance imaging/magnetic resonance cholangiopancreatography demonstrated a “double-duct sign” with dilated bile and pancreatic ducts concerning for malignancy, although no mass was visualized (**Figure 1**). There were innumerable lesions within the liver parenchyma, described as a “starry sky” appearance and consistent with metastatic disease (**Figure 2**). The patient was referred for biopsy and biliary drainage.

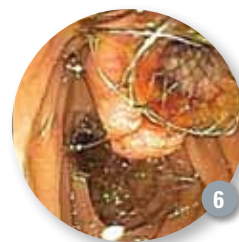
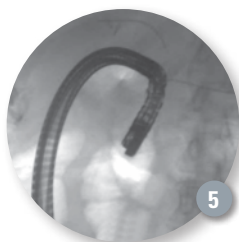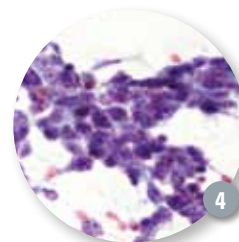
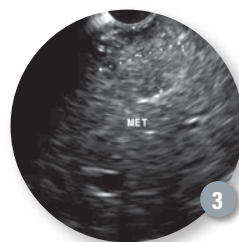
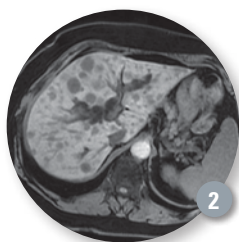
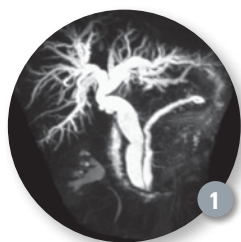PROCEDURE AND OUTCOME

Combined endoscopic ultrasound (EUS) and endoscopic retrograde cholangiopancreatography (ERCP) were performed under monitored anesthesia care (MAC). The EUS revealed multiple, subtle lesions in the left lobe of the liver, up to 1.8 cm (**Figure 3**), as well as a 2cm ampullary mass. An EUS-fine needle aspiration (FNA) biopsy was performed using the Expect™ EUS-FNA Needle (22G) without suction. One pass was performed through the stomach. Rapid-on-site-examination by the cytopathologist showed a highly cellular specimen and confirmed the diagnosis of poorly differentiated carcinoma, consistent with primary ampullary lesion that was apparent on endoscopic inspection (**Figure 4**).

The patient was then repositioned and an ERCP was performed using a Hydratome™ RX Sphincterotome and a 0.035mm Hydra Jagwire™ High Performance Guidewire. The ampullary mass required a long position for approach. After wire cannulation of the pancreatic duct, a “double wire” technique was used to access the bile duct (**Figure 5**). A 4cm fully-covered WallFlex™ Stent was placed for symptom palliation (**Figure 6**). The flexibility of the WallFlex Stent delivery system allowed for deployment in the highly-angulated long position. The patient tolerated the procedure well and was discharged home two hours later.

BACKGROUND AND DISCUSSION

Combined EUS and ERCP for suspected pancreaticobiliary malignancy have been shown to be safe and effective. Reported complication rates are no higher than the component procedures¹. **This is especially helpful for patients when long travel is required to access advanced endoscopy.** In the setting of disseminated liver metastasis, the Expect EUS-FNA 22G Needle provides sufficient material for rapid on-site interpretation, with few needle passes. In this case, the Hydratome RX Sphincterotome allowed for efficient biliary access despite difficult anatomy, with a pancreatic duct wire aiding in physician-guided guidewire access of the common bile duct. With the diagnosis of metastatic cancer established, the endoscopist can choose an appropriate biliary stent for the clinical situation (a covered metal stent in this case to provide durable biliary drainage). The combined procedure required a modest total anesthesia time of 86 minutes.



References:

- 1) William A. Ross, Sanjeev M. Wasan, Douglas B. Evans, Robert A. Wolff, Leonard V. Trapani, Gregg A. Staerke, Thomas Prindiville, Jeffrey H. Lee. Combined EUS with FNA and ERCP for the evaluation of patients with obstructive jaundice from presumed pancreatic malignancy, *Gastrointestinal Endoscopy*, Volume 68, Issue 3, September 2008, Pages 461-466, ISSN 0016-5107, 10.1016/j.gie.2007.11.033.

NOTE: Use of the WallFlex Biliary RX Fully Covered Stent for the treatment of benign strictures or stenoses has not been cleared for use in the United States.

WARNING: The safety and effectiveness of the WallFlex Biliary Stent for use in the vascular system has not been established.

Expect 19ga Flex Needle for Pre-Operatory Diagnosis of Neuroendocrine Tumor



CASE PRESENTED BY:

CARLO FABBRI

Unit of Gastroenterology and Digestive Endoscopy, AUSL Bologna Bellaria-Maggiore Hospital, Bologna, ITALY

ANNAMARIA POLIFEMO

Unit of Gastroenterology and Digestive Endoscopy, AUSL Bologna Bellaria-Maggiore Hospital, Bologna, ITALY

ADELE FORNELLI

Unit of Anatomic Pathologic, AUSL Bologna Bellaria-Maggiore Hospital Bologna, ITALY

NICOLA ZANINI

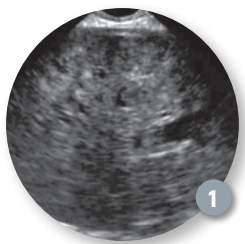
Department of Surgery, AUSL Bologna Bellaria-Maggiore Hospital Bologna, ITALY

ANTONELLA MAIMONE

Postgraduate School of Gastroenterology, University of Ferrara, ITALY

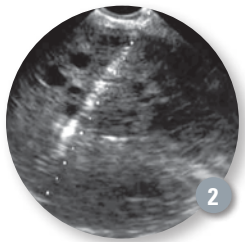
PAOLA BACCARINI

Unit of Anatomic Pathologic, AUSL Bologna Bellaria-Maggiore Hospital Bologna, ITALY



PATIENT HISTORY

The patient is a 35-year-old female who came for medical attention because of abdominal swelling of short duration. No other symptoms were present and the patient's past medical history was unremarkable. An abdominal computerized tomography (CT) scan revealed the presence of a mass of the cephalopancreatic region characterized by dishomogeneous contrast enhancement in all the vascular phases.



PROCEDURE


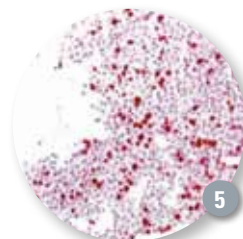
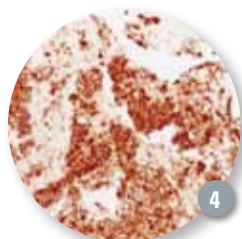
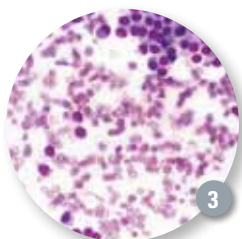
The endoscopic ultrasound (EUS) evaluation showed a large bulging of the posterior gastric wall that at time of ultrasound study appeared as an isoecic solid lesion between the pancreatic body and gastric wall (**Figure 1**); the lesion had regular margin and multiple anechoic lakes. After EUS evaluation, the lesion was punctured with an Expect™ 19ga Flex Needle (**Figure 2**) and 10-20 to-and-fro movements were performed with minimal negative pressure provided by pulling the stylet slowly. The specimen was expelled onto a glass slide and all visible core placed into a formalin bottle after measurement of core specimen lengths. A smear was immediately stained with Diff Quick (**Figure 3**) and the remaining material was placed in a vial containing 4% formalin. On cytological/histological preparations, many neoplastic cells with relatively monotonous appearance, round to ovoid nuclei with coarsely clumped chromatin, were seen. Sufficient material was present to perform multiple immunohistochemical analysis, in particular chromogranin (**Figure 4**) (intensely positive) and ki-67, greater than 20%, (**Figure 5**). The patient underwent DC-pancreatectomy (**Figure 6**), confirming the preop-diagnosis of neuroendocrine carcinoma (a Grade 3 neuroendocrine tumor according to World Health Organization classifications, 2010).

POST PROCEDURE

The procedure was well tolerated by the patient and no procedure- or sedation-related immediate or delayed complications were observed.

CONCLUSION

For these types of situations EUS-FNA for tissue assessment is often essential. This case report shows the **use of the Expect 19Ga Flex Needle with the technique of minimal negative pressure is able to obtain sufficient material for an accurate pre-surgical cytological diagnosis.**



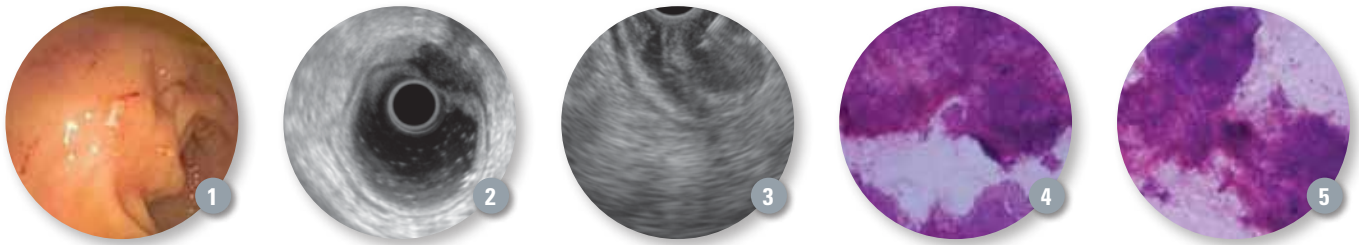
EUS-FNA is Effective Tool to Help Diagnose Rectal Endometriosis



CASE PRESENTED BY:

VIKRAM BHATIA, M.D.

Associate Professor
Gastroenterology and Hepatology
Institute of Liver and Biliary Sciences
New Delhi, INDIA



PATIENT HISTORY

A 41-year-old female patient presented with rectal pain and excessive mucus discharge. She had undergone a hysterectomy three years prior, which had revealed uterine adenomyosis. Upon colonoscopy a submucosal bulge was seen at 10cm from the anal verge, with hyperemic and slightly irregular overlying mucosa (**Figure 1**). Endoscopic biopsies only showed mild chronic inflammation. Eccentric rectal wall thickening, with a hypointense signal on T2-weighted images was seen on magnetic resonance (MR) imaging of the pelvis.

PROCEDURE

An endoscopic ultrasound (EUS) procedure was done after preparing the colon with 2L of polyethylene glycol solution. The procedure was done in a left-lateral decubitus position. An electronic radial scanning EUS scope (GF-UE160) was used. The rectal lumen was distended with de-aerated water and imaging was done as the scope was withdrawn from the recto-sigmoid junction. The bladder was aligned at the top of the screen for anatomic orientation. The normal rectal wall was demonstrated as a five-layered structure. Just below the level of the bladder base, a hypoechoic lesion with small internal anechoic areas was seen on the anterior wall. The lesion measured 12mm in the long axis. This lesion seemed to extend into the rectal wall from the outside, expanding the muscularis-propria, with an irregular extension into the submucosal layer (**Figure 2**). No enlarged peri-rectal nodes were seen. Subsequently,

a linear EUS scope (GF-UCT140) was passed and the above mentioned lesion was localized. A 22 gauge Expect™ EUS-FNA Needle was used to puncture the lesion. The tip visibility was good and the needle could be precisely placed in the small mural lesion. Three fine needle aspiration (FNA) passes were made (**Figure 3**).

The smears showed adequate cellularity with glandular and stromal components (**Figures 4 and 5**). The glandular epithelial cells were arranged in sheets and groups displaying peripheral palisading, and had a uniform round to oval nucleus, with small amounts of cytoplasm. Stromal fragments were composed of loosely arranged groups of spindle cells. Few hemosiderin-laden macrophages were interspersed. A diagnosis of endometriosis could be made based on the EUS-FNA aspirate.

COMMENTS

Bowel infiltration may be seen in 5% to 37% patients with pelvic endometriosis. Computed tomography and MR scans are less effective than EUS for detecting involvement of the rectosigmoid. The deposits of bowel endometriosis are generally submucosal, and are therefore not accessible using standard endoscopic biopsy forceps. For deeply infiltrating endometriosis drug therapy is less effective, and many patients will require surgery. **EUS-FNA is an underutilized, but effective tool for diagnosing the presence and extent of rectal endometriosis.**

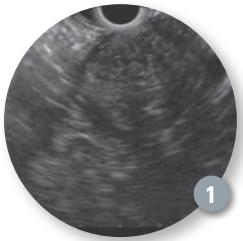
Obtaining Ample Core Tissue Helps in Evaluation of Pancreatic Head Lesion



CASE PRESENTED BY:

DOUMIT BOUHAI DAR, M.D.

Virginia Commonwealth University
Richmond, Virginia, USA



PATIENT HISTORY

A 76-year-old male patient presented to his primary care provider with the chief complaint of abdominal pain. An incidental finding of a pancreatic head mass was found during a work up for hydronephrosis. An endoscopic ultrasound (EUS) evaluation of the pancreatic head mass and tissue sampling was requested.

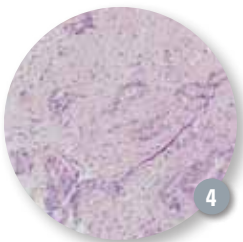
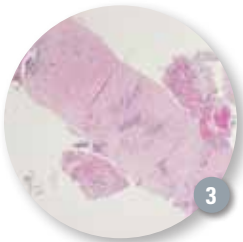
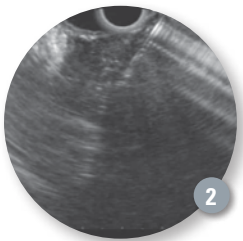
PROCEDURE

Endoscopic Ultrasound revealed an irregular hypoechoic mass measured at 36 x 33 mm (**Figure 1**). Transgastric EUS-guided fine-needle aspiration (FNA) was performed with an Expect™ EUS-FNA 19ga Flex Needle (**Figure 2**). A total of three passes were made. Bedside preliminary cytology examination was suspicious for adenocarcinoma given a large quantity of material was obtained during the procedure. Official pathology result confirms the initial suspicion (**Figure 3 and 4**).

COMMENTS

This case nicely illustrates the utility of EUS in the evaluation of a pancreatic head lesion. However, the diagnostic yield of FNA is often hindered by insufficient quantity of pathological specimen that is acquired during the procedure.

A significant amount of core tissue nonetheless was obtained with this Expect 19ga Flex EUS-FNA needle and helped expedite the surgical and oncological management of this patient.



Pancreatico-Biliary Evaluation Using the SpyGlass Direct Visualization System



CASE PRESENTED BY:

FABIO D'AMORE, M.D.

DR. A. BORRUTO, M.D.

San Vincenzo Hospital, Taormina
Sicily, ITALY

INTRODUCTION

Clinical articles show a computerized tomography (CT) scan with contrast and magnetic resonance cholangiopancreatography (MRCP) have a higher accuracy in comparison with endoscopic retrograde cholangiopancreatography (ERCP) in intraductal papillary mucinous neoplasm (IPMN) diagnosis, although these same results may not be found with < 2cm lesions. In this procedure we tested a new way to make a diagnosis. We improved the ERCP specificity using the SpyGlass™ Direct Visualization System in the pancreas to confirm IPMN already identified by CT scan with contrast magnetic resonance imaging.

PATIENT HISTORY

An 82-year-old female presented with perceived abdominal pain, significant weight loss and recurring pancreatitis. Marker Ca 19-9 values were normal. A CT scan with contrast showed a moderate mass in front of pancreatic head. Initially, the imaging study suggested IPMN (**Figure 1**).

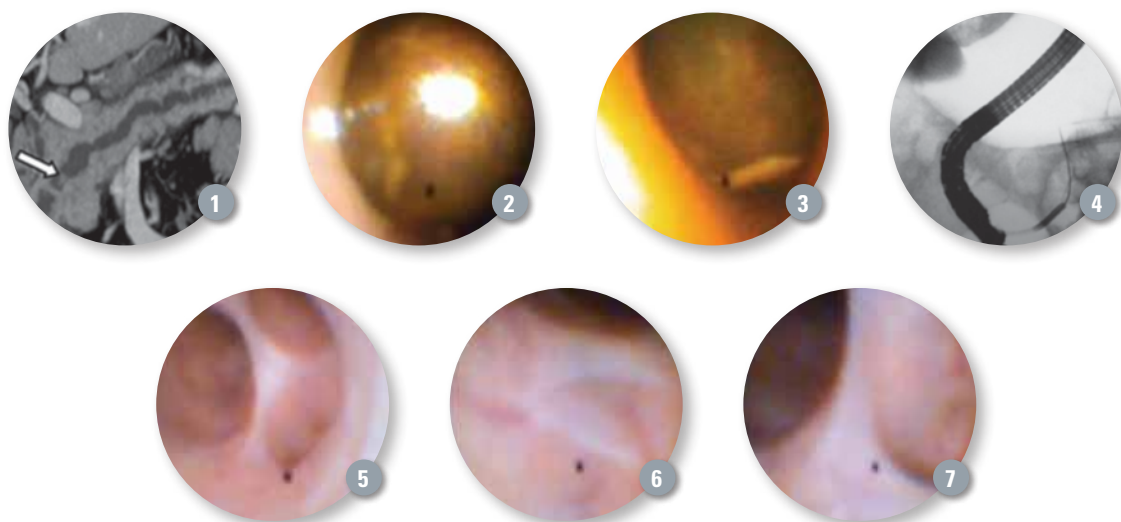
PROCEDURE

Magnetic Resonance Imaging showed an inert mass that caused the dilation of the pancreatic duct and a probable neoplasia that involved the Vater papilla and dilated the common bile duct. After further analysis we performed an ERCP that showed a hypertrophic papilla with a large stone but without neoplasia. We performed a SpyGlass System procedure inside the biliary system, which confirmed the biliary stone diagnosis contradicting the first neoplasia hypothesis (**Figures 2 and Figure 3**). After the biliary evaluation, we introduced the SpyGlass System inside the pancreatic duct (**Figure 4**).

The SpyGlass System allowed confirmation of the presence of a mucus collection site inside the Wirsung duct (This site is most likely the result of previous pancreatitis events) without presence of pathology (**Figures 5, 6 and 7**).

PATIENT OUTCOME AND DISCUSSION

Today, the patient has gained 10Kg and her condition is good. **Pancreatico-biliary evaluation using the SpyGlass Direct Visualization System allows us to obtain the correct diagnosis without using more costly and invasive technologies.**



Boston Scientific

'Joins the Fight' Against Colorectal Cancer

Throughout the month of March, Boston Scientific and its U.S. employees helped bring attention to the prevalence and prevention of cancers of the colon and rectum as part of Colorectal Cancer Awareness Month. The company supported the cause through sponsorship, donations and outreach activities.

Boston Scientific supported Fight Colorectal Cancer (FCC), the leading colorectal cancer advocacy organization in the U.S., through a charitable donation to its "One Million Strong" campaign. The donation funded a 30-second public service announcement (PSA) that was shown on the NASDAQ MarketSite Tower electronic billboard in Times Square in New York, and featured Boston Scientific employees flexing their muscles in support of the fight against colorectal cancer. The PSA highlighted the importance of early detection and ran every hour from March 1-7.

Other activities supported community outreach efforts. Through a charitable donation Boston Scientific supported a group of five physicians from the Dallas Endoscopy Center to screen high-risk colorectal cancer patients who would have otherwise not had access to these screenings due to a lack of medical insurance. Precancerous polyps were found in 6 of the 19 patients who were screened. Having the screenings may prevent the patient from developing colorectal cancer within the next 10 years. Boston Scientific also participated in the health and wellness pavilion at the Black Expo held March 9 in Charleston, South Carolina. The expo helps raise awareness of colorectal cancer, which is especially prevalent among African-American males over the age of 50.

As a way to raise awareness throughout the company, during the month of March, Boston Scientific employees collected donations for colorectal cancer by selling colorectal cancer awareness pins at its Natick and Marlborough, Mass. locations. The proceeds are being matched by Boston Scientific and donated to the Colon Cancer Alliance to support its screening mission and its patient and research programs.

Boston Scientific sponsored a public service announcement in New York's Times Square as part of Colorectal Cancer Awareness Month.



Boston Scientific's Close the Gap is an ongoing program focused on educating all individuals who are at risk of developing colorectal cancer and reducing health disparities in diagnosis and treatment of the disease, especially among African American males over the age of 50 who have not been screened for colorectal cancer.



Nothing 'Lost in Translation' for Coyal Facility Employees

During a visit to Boston Scientific's Coyal manufacturing facility in Costa Rica, global product manager, Jim Petrou, made use of his Spanish language skills to help educate employees about biliary disease states and procedures, and how the products they produce are used. The presentation along with a question and answer session was conducted solely in Spanish to the more than 150 employees who work at the facility where some of Boston Scientific's sphincterotomes and guidewires are produced.

After his presentation Petrou spoke with employees who expressed their appreciation for having the opportunity to learn how Boston Scientific products address the needs of physicians and helps patients. Petrou commented, "It was clearly an empowering experience for all

involved. Helping people understand the importance of what they do and what it means for the customer is a big step toward getting people fully committed to focusing on quality."

“It was clearly an empowering experience for all involved. Helping people understand the importance of what they do and what it means for the customer is a big step toward getting people fully committed to focusing on quality.”

— **Jim Petrou**, Global Product Manager

Resolution Clip Now Has Magnetic Resonance Conditional Claim

In December 2012 Boston Scientific received a U.S. 510(k) clearance from the Food and Drug Administration and in the European Union was CE Marked for a Magnetic Resonance (MR) conditional claim. Both non-clinical and simulated tissue testing were completed to demonstrate that the Resolution™ Clip is MR conditional to the American Society of Testing and Materials F2503 standard.

"With this new conditional claim, physicians can use Resolution Clip knowing that a patient could undergo an MRI with the clip still in place," said Chris Davis, product manager at Boston Scientific. "Before the claim, patients had to undergo an additional screening to ensure the clip had passed prior to having an MRI. This is a time-saving benefit for the patient and a hospital cost savings as well."¹

Boston Scientific pursued the necessary testing for the conditional claim due to the continued adoption of Resolution Clips to provide hemostasis for gastrointestinal bleeds, high retention rates in patients and customer inquiries regarding the compatibility of clips and MR imaging scanners.

More than **3.5 million Resolution Clips** have been placed and over **220 clinical studies** have been published since the device's launch in 2004.

¹According to ASTM F2503 in a static magnetic field of 1.5 and 3 Tesla. For a complete list of conditions consult the Directions for Use.

Prior to FDA clearance of the MR conditional claim, MR imaging was contraindicated in patients who had clips placed within their gastrointestinal tract.



Webcast for Viewing on Demand:

Tissue is the Issue: EUS FNA and the Role of Integrated Cytopathology

Hear from **Robert Hawes, M.D.**, medical director, Institute for Minimally Invasive Therapy Florida Hospital, Orlando, Florida (moderator); **Shyam Varadarajulu, M.D.**, medical director, Center for Interventional Endoscopy, Florida Hospital, Orlando, Florida; and **Shantel Hébert-Magee, M.D.**, assistant professor, Cytopathology Section at the Division of Anatomic Pathology,

University of Alabama at Birmingham, Birmingham, Alabama on the increasingly important role cytopathology is playing in endoscopic ultrasound fine-needle aspiration (FNA).

To view the webcast (Limited Time):

http://tv.hbgroupinc.com/events/bsci/tissue_is_the_issue/

Can be viewed on the iPad or smart phone!

ACCESS Magazine was produced in cooperation with several physicians. The procedures discussed in this document are those of the physicians and do not necessarily reflect the opinion, policies or recommendations of Boston Scientific Corporation or any of its employees.

Results from case studies are not predictive of results in other cases. Results in other cases may vary.

CAUTION: The law, including Federal (USA) law, restricts these devices to sale by or on the order of a physician. Indications, contraindications, warnings and instructions for use can be found in the product labeling supplied with each device.

WARNING: The safety and effectiveness of the WallFlex Biliary Stent for use in the vascular system has not been established.

Advanix, CRE, EndoVive, Enhancing Patient Outcomes, Delivering Total Value, Expect, Hydra Jagwire, Hydratome, Jagwire, NaviFlex, Radial Jaw, Resolution, SpyGlass, TRUetome, WallFlex are unregistered or registered trademarks of Boston Scientific or its affiliates. All other trademarks are property of their respective owners.

©2013 Boston Scientific Corporation or its affiliates. All rights reserved.

DINEND2315EA

ENDO-152806-AA 10M May 2013

**Boston
Scientific**